

# ABNORMALITIES OF THE OPTIC NERVE AND RETINA

*Laura J. Balcer and Sashank Prasad*

Optic Nerve Anatomy and Physiology 184	Congenital Optic Disc Anomalies 192
The Swollen Optic Disc 184	Tilted Optic Disc 192
Unilateral Optic Disc Edema 184	Optic Nerve Dysplasia 192
Bilateral Optic Disc Edema 188	Retinal Disorders 193
Pseudopapilledema 190	Retinal Arterial Disease 193
Optic Neuropathies with Normal-Appearing Optic Discs 191	Retinal Vein Occlusion 194
Unilateral Presentations 191	Retinal Degenerations 194
Bilateral Presentations 192	Uveoretinal Meningoencephalitis Syndromes 195
Optic Neuropathies with Optic Atrophy 192	Phakomatoses 195

Disorders of the optic nerve and retina are common causes of afferent visual loss in clinical neurology. The diagnosis of optic neuropathy should be considered when the following clinical features are present: (1) visual loss in association with a swollen, pale, or anomalous optic disc or (2) visual loss (affecting visual acuity, color vision, or visual field) combined with an afferent pupillary defect (APD) (see Chapter 17), despite a normal disc appearance. The specific cause for optic neuropathy in a given patient often can be established without the need for neuroimaging on the basis of clinical history (i.e., character/progression of vision loss), whether one or both eyes are

involved, the pattern of visual field loss, and the optic disc appearance. Acquired optic neuropathies can be classified according to whether the optic disc appears normal, swollen, or pale. Table 15-1 groups possible causes by appearance of the optic disc. Chapter 14 describes the various patterns of visual field loss and clinical history typically elicited in patients with specific optic nerve disorders. This chapter presents the differential diagnosis for optic neuropathies based on the optic disc appearance and discusses retinal disorders of particular interest in neurology. Many of the entities described in this chapter are discussed in more detail in Chapter 39.

**TABLE 15-1 Causes of Unilateral and Bilateral Optic Neuropathy Categorized by Optic Disc Appearance**

EDEMA		TOUS		NORMAL-APPEARING		ATROPHIC	
UNILATERAL	BILATERAL	UNILATERAL	BILATERAL	CUPPED	NOT CUPPED		
Optic neuritis	Papilledema (increased intracranial pressure)	Retrolubar neuritis	Tobacco-alcohol	Glaucoma	Any optic neuropathy		
Ischemic optic neuropathy	Malignant hypertension	Compressive lesion	Nutritional	Giant cell arteritis			
Orbital tumor	Diabetic papillopathy	Infiltration: granulomatous, carcinomatous, lymphomatous	Drugs				
Other: central retinal vein occlusion, papillophlebitis, infiltrative disorders, Leber's hereditary optic neuropathy	Other: anemia, hypoviscosity, severe hypotension		Toxins Hereditary				

Reprinted with permission from Beck, R. W., & Smith, C. H. 1988, *Neuro-Ophthalmology: A Problem-Oriented Approach*, Little, Brown, Boston.

## OPTIC NERVE ANATOMY AND PHYSIOLOGY

Light stimulates retinal photoreceptors, whose signal is modulated by bipolar, horizontal, and amacrine cells before stimulating a ganglion cell. Retinal ganglion cells are of two types: M (large) cells, which project to the magnocellular layer and are specialized for motion perception and coarse stereopsis, and P (small) cells, which project to the parvocellular layer and are specialized for high spatial resolution, color vision, and fine stereopsis. Temporal retinal fibers form arcuate bundles around the fovea, respecting the midline horizontal raphe, and then enter the optic disc superiorly and inferiorly. Optic nerve fibers exit the globe at the scleral canal, where they are physically supported by collagen and elastin of the lamina cribrosa and metabolically supported by intertwining astrocytes. Once nerve fibers pass the lamina cribrosa, they are supported by oligodendrocytes and are myelinated. The structural support is weakest at the superior and inferior poles, which possibly explains the preferential involvement of these fibers in the setting of increased intraocular pressure. Immediately posterior to the globe, the optic nerve fibers are subjected to intracranial pressure transmitted through the investing meninges. After leaving the orbit, the nerve enters the optic canal, which is a narrow space within the lesser sphenoid wing. In this space, the nerve is particularly vulnerable to trauma or compressive lesions (Balcer, 2001, Liu et al., 2001).

Effective axonal transport is essential for maintenance of the ganglion cell axon structure and function. Orthograde transport (away from the ganglion cell body) occurs at two speeds: 400 mm per day for proteins and neurotransmitters packaged in vesicles, and 1 to 4 mm per day for structural elements of the cytoskeleton. Many pathological processes interfere with axonal transport, ultimately causing damage to the optic nerve (Liu et al., 2001).

The ophthalmic artery, from the internal carotid artery, ultimately provides all blood supply to the eye. It branches into multiple short posterior ciliary arteries and the central retinal artery. The short posterior ciliary arteries provide blood supply to the optic nerve head below its surface, as well as to the subretinal choroid. Each posterior ciliary artery supplies a variable, segmental territory of the optic nerve head, and because anastomoses in this blood supply are scant, it can suffer watershed ischemia during hypoperfusion. Furthermore, the segmental blood supply underlies the sectoral disc swelling or atrophy that results from interrupted flow of a posterior ciliary artery and subsequent optic nerve infarction (Balcer, 2001, Liu et al., 2001).

## THE SWOLLEN OPTIC DISC

In assessing an elevated optic disc, the examiner first must determine whether acquired disc edema (true disc swelling) is present or if the disc appearance is that of pseudopapilledema. This distinction is important. True papilledema may be accompanied by symptoms of elevated intracranial pressure, such as headache, transient visual obscurations with change in posture, nausea, and vomiting. In addition, papilledema commonly is

bilateral, in contrast with optic neuropathies, which typically are unilateral, such as optic neuritis or ischemic optic neuropathy. Causes of pseudopapilledema include congenital anomalies, myelinated nerve fibers, and optic nerve head drusen.

## Unilateral Optic Disc Edema

In cases of true optic disc edema, it should be determined if disc swelling and optic nerve dysfunction are unilateral or bilateral. The most common causes of unilateral optic disc edema are nonarteritic anterior ischemic optic neuropathy (AION), optic neuritis (termed *papillitis* when disc swelling is present), and orbital compressive lesions (see Table 15-1). As a rule, optic nerve function is abnormal in each of these entities. Although characteristics of the optic disc appearance may overlap among AION, optic neuritis, and compressive optic neuropathies, certain features may be suggestive of a specific diagnosis. In AION the disc typically has a chalky-white edematous appearance, and disc hemorrhages are likely to be present (Fig. 15-1). AION is associated with disc edema (by definition), which often is sectoral, as a result of the segmental blood supply provided by the posterior ciliary arteries. The combination of findings suggestive of AION and retinal artery occlusion strongly implies ophthalmic artery involvement. Papillitis, on the other hand, is suggested by a cellular reaction in the vitreous overlying the optic disc and the presence of retinal exudates (Fig. 15-2). In patients with acute demyelinating optic neuritis (the most common form of optic neuritis, associated with multiple sclerosis [MS]), optic disc swelling is present in about 33% of patients. Disc hemorrhages are uncommon in these patients, however, so this finding should suggest an alternative diagnosis. Finally, chronic disc edema due to compressive lesions often is accompanied by optic chiasm vessels and glistening white bodies on the disc surface (pseudodrusen from extruded axoplasm) (Fig. 15-3). Optociliary shunt vessels represent communications between the ciliary and retinal venous circulations. In addition to occurring with orbital tumors compressing the optic nerve, such as a meningioma, they also can be seen with retinal vein occlusions, glaucoma, malignant hypertension, chronic papilledema, and as a congenital variant.

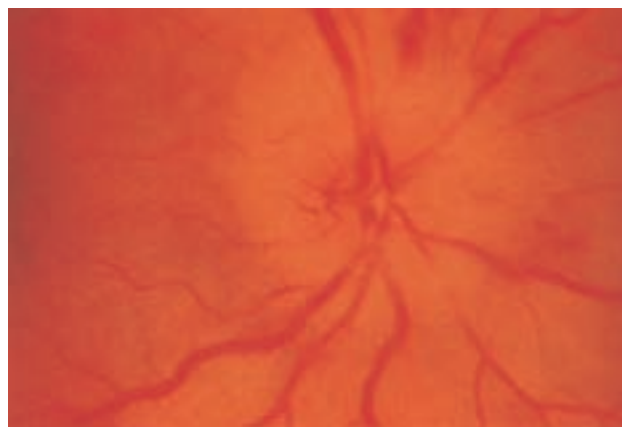
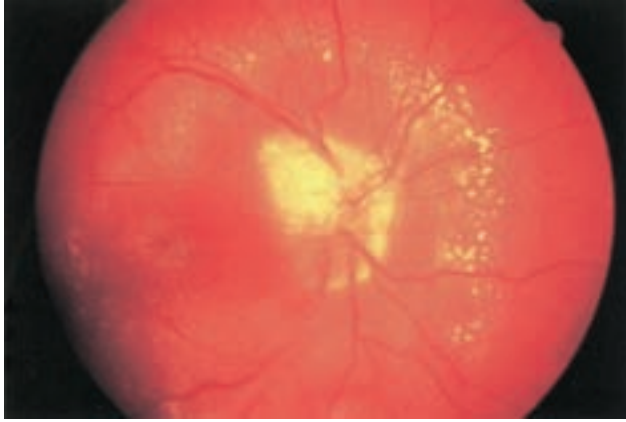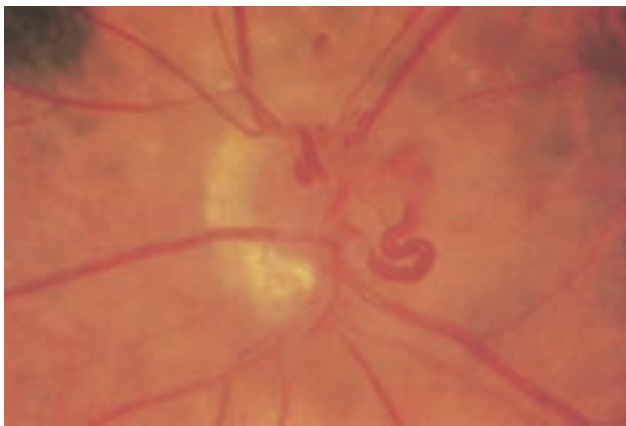


FIGURE 15-1 Anterior ischemic optic neuropathy in a 52-year-old woman.



**FIGURE 15-2** Neuroretinitis in a 6-year-old boy. Such exudates, although usually not present in optic neuritis, indicate an inflammatory cause for the disc edema. (Reprinted with permission from Beck, R. W., & Smith, C. H. 1988, *Neuro-Ophthalmology: A Problem-Oriented Approach*, Little, Brown, Boston.)

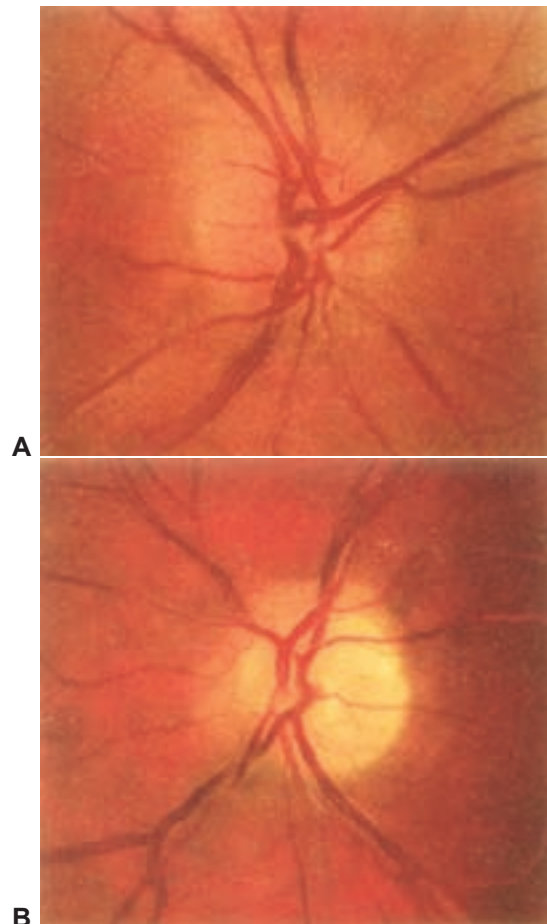


**FIGURE 15-3** Optic disc swelling and optociliary shunt vessels in a 44-year-old woman with a sphenoid meningioma. (Reprinted with permission from Beck, R. W., & Smith, C. H. 1988, *Neuro-Ophthalmology: A Problem-Oriented Approach*, Little, Brown, Boston.)

Despite the suggestive patterns in the appearance of the optic nerve, it often is not possible to distinguish among papillitis, AION, and compressive optic neuropathies on this basis alone. In such instances, the diagnosis also is based on the clinical history (the acuity of vision loss) and the pattern of the visual field deficit. Visual acuity typically is reduced in optic neuropathies but does not correlate perfectly with the extent of optic nerve dysfunction, so it is a somewhat insensitive measure. On the other hand, poor color vision, particularly out of proportion to loss of acuity, is a very sensitive indicator of optic neuropathy. Finally, the relative afferent pupillary defect, as diagnosed by the swinging flashlight test, reliably identifies optic nerve pathology. Vision loss generally is slowly progressive in patients with compressive lesions and is of sudden onset with subsequent improvement in those with optic neuritis but with no or incomplete improvement in patients with

AION. Both optic neuritis and compressive lesions generally produce some form of central visual loss (central scotoma), whereas AION typically produces a nerve fiber bundle-type field defect (originating from, and involving, the physiologic blind spot). The scotoma typically will respect the horizontal meridian, given the arrangement of retinal fibers traveling to the optic disc. However, considerable overlap exists in the patterns of visual field loss for optic neuropathies.

Consecutive involvement of the fellow eye also is an important clinical feature that may identify the cause of an optic neuropathy. For example, AION affects the two eyes consecutively in up to 25% of cases. When the second eye is affected in AION, optic atrophy develops in one eye, and disc edema with decreased acuity develops in the fellow eye; this clinical presentation is called the *pseudo-Foster Kennedy syndrome* (Fig. 15-4). (A true Foster Kennedy syndrome is produced by optic atrophy in one eye due to compression, typically from an expanding tumor, and papilledema with relatively spared acuity in the fellow eye secondary to increased intracranial pressure.)



**FIGURE 15-4** Pseudo-Foster Kennedy syndrome from acute ischemic optic neuropathy (disc edema) in the right eye (A) and from previous ischemic optic neuropathy (optic atrophy) in the left eye (B) in a 53-year-old man. (Reprinted with permission from Beck, R. W., & Smith, C. H. 1988, *Neuro-Ophthalmology: A Problem-Oriented Approach*, Little, Brown, Boston.)

## Optic Neuritis

*Optic neuritis* is the term for an inflammatory optic neuropathy specifically caused by demyelinating disease. Visual loss in the affected eye typically occurs rapidly, over several hours to a few days. Decreased color vision and contrast sensitivity are highly characteristic (Baier et al., 2005). In addition, pain with eye movements precedes the vision loss in approximately 90% of cases. The pain typically lasts 3 to 5 days, and if it persists for longer than 7 days, optic neuritis should be considered less likely, and further workup should be pursued. Visual field defects commonly are present but can be either diffuse or discrete scotomas and are nonspecific. Funduscopy reveals mild disc swelling in approximately one third of affected eyes, which is considerably less prominent than the disc swelling associated with papilledema (Balcer, 2006; Beck, 1998).

The prognosis for recovery of vision generally is good but is related to the severity of the initial deficit. Recovery typically begins within 1 month. The likelihood of progression of optic neuritis to MS is best predicted by brain MRI at the time of diagnosis. In the Optic Neuritis Treatment Trial, the risk of development of MS within 10 years was 56% among patients with one or more characteristic brain lesions, whereas it is 22% if the MRI was normal (Beck et al., 2003). Recent studies support the early use of available immunomodulating treatments to reduce the likelihood of progression to MS within 2 to 5 years. With features that are atypical for optic neuritis, however, such as painless visual loss, severe disc edema, disc or peripapillary hemorrhages, or a macular exudate, the risk of developing MS is significantly lower.

Neuromyelitis optica (NMO), or Devic's disease, is characterized by necrotizing demyelinating lesions of bilateral optic nerves and the spinal cord. It is believed to be a humorally mediated disease distinct from MS. The spinal lesion characteristic of NMO often extends contiguously over three or more vertebral segments. A serum antibody, NMO-IgG, which targets the autoantigen aquaporin-4, may be a useful marker in diagnosing the condition, although the exact specificity remains unknown. Treatment with rituximab, a chemotherapeutic monoclonal antibody, may be of particular benefit in this group of patients (Wingerchuk, 2006).

Treating optic neuritis with high-dose intravenous steroids reduces the risk of developing MS over the following 2 years. In the long term, however, this acute treatment is unlikely to affect the likelihood of progression to MS. In addition, intravenous steroids may hasten visual recovery, particularly for visual fields and contrast sensitivity but do not significantly affect long-term visual outcomes. Because low-dose oral corticosteroids are associated with an increased risk of recurrence of optic neuritis, this therapy should be avoided (Beck et al., 2004; Trobe et al., 1996).

## Ischemic Optic Neuropathy

Arteritic anterior ischemic optic neuropathy usually is related to temporal arteritis and always associated with disc swelling. Rarely, this entity can affect the nerve only proximal to the lamina cribrosa and manifest without disc swelling; this situation is termed *arteritic posterior ischemic optic neuropathy*. The prevalence of temporal arteritis increases with age, and most patients are older than 70 years of age. Acute vision loss is

the presenting symptom in 7% to 60% of cases and generally is significantly more severe than in nonarteritic AION. In approximately 25% of cases, vision is limited to perception of hand motion only, or light perception is absent (Balcer and Galetta, 2003).

Medium-sized to large arteries (predominantly those in extracranial locations), which contain an elastic lamina, are affected. The condition is associated with polymyalgia rheumatica, consisting of proximal muscle ache, arthralgia, and stiffness, as well as with jaw claudication, fever, malaise, and scalp tenderness. The diagnosis is suggested by an elevated erythrocyte sedimentation rate and C-reactive protein and is confirmed by evidence of giant cells and inflammation in temporal artery biopsy specimens. Treatment with corticosteroids should not be delayed for the artery specimen to be obtained. Some evidence indicates that intravenous steroids may help to delay the progression of visual loss and to decrease the likelihood of fellow eye involvement. The prognosis for recovery in the affected eye, however, is poor despite treatment (Hall and Balcer, 2004).

Nonarteritic AION is the most common cause of unilateral optic nerve swelling in adults older than 50 and commonly is associated with vascular risk factors such as diabetes or hypertension. Other risk factors include a crowded optic nerve head and nocturnal hypotension, possibly precipitated by antihypertensive therapy (Arnold, 2003; Matthews, 2005).

Prognostically, many patients will have a stable deficit, although some may experience progression over a month, and the expected rate of spontaneous improvement is high. In 30% to 40% of patients, subsequent involvement of the fellow eye occurs, and this rate is increased by the presence of vascular risk factors. Recurrence in an affected eye, however, is very rare. There does not appear to be a significantly higher rate of stroke in patients with nonarteritic ischemic optic neuropathy (Arnold and Levin, 2002).

Posterior (retrobulbar) ischemic optic neuropathy is rare, but is often a sign of giant cell arteritis. The workup should therefore include an evaluation for arteritis, as well as for inflammatory and infiltrative conditions. Sometimes ischemic optic neuropathy without significant disc edema can occur after severe blood loss and shock (Chang and Miller, 2005).

## Other Causes

Paranasal sinus disease can cause a condition that mimics optic neuritis, with acute optic neuropathy and pain on eye movements, or can cause a progressive optic neuropathy resulting from compression. Optic neuropathy due to sinusitis and mucocele should be considered in patients who have clinical evidence of optic neuritis with seemingly atypical features, particularly in elderly patients with severe sinus disease, a history of fevers, ophthalmoplegia, or progression of vision loss beyond 2 weeks.

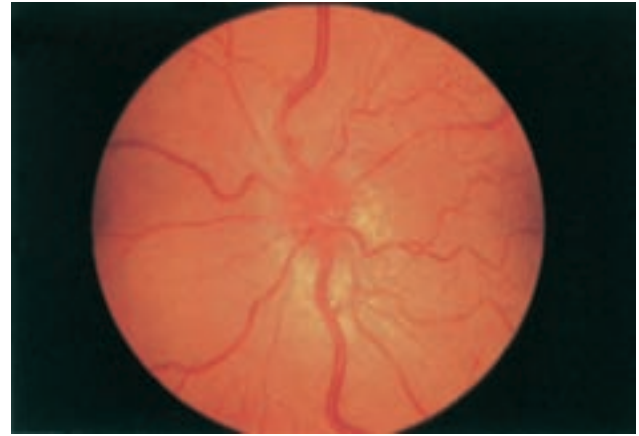
Compressive lesions producing disc edema almost always involve the intraorbital or intracranial portions of the optic nerve. Meningiomas of the optic nerve sheath or sphenoid wing (involving the canal) are common causes of compressive unilateral disc edema (see Fig. 15-3). Intracranial compressive lesions only rarely produce disc edema, unless they are large enough to raise intracranial pressure. Graves' ophthalmopathy (thyroid eye disease) also can cause compressive disc edema, by means of enlargement of extraocular muscles and entrapment of the optic nerve.

Macular exudates (often in a star pattern around the fovea), in association with disc swelling, is termed *neuroretinitis* and

can be important in distinguishing neuroretinitis from acute demyelinating optic neuritis. The initial clinical presentation of these conditions may be similar, but the characteristic macular star will appear within 1 to 2 weeks, establishing the diagnosis. The distinction is critical because neuroretinitis has no association with an increased risk of MS. Often, the cause is infectious, including cat-scratch disease (due to *Bartonella henselae*), Lyme disease, toxoplasmosis, or syphilis. *Bartonella* infection is self-limited, and no treatment is indicated, but doxycycline may be effective in severe cases (Balcer and Beck, 2005).

Retinal vein occlusion occasionally manifests primarily as optic disc edema with minimal or no retinal hemorrhages. Papillophlebitis is a syndrome of presumed retinal vein inflammation producing optic disc edema in young adults (Fig. 15-5), with dilated retinal veins. Other than enlargement of the blind spot, the visual field usually is normal. This condition tends to resolve without residual vision loss. In older patients, retinal vein obstruction may be caused by compression of the vein by an atherosclerotic artery. The disc typically appears extremely hyperemic (Fig. 15-6), and optociliary shunt vessels also may be present. As with papillophlebitis, visual function usually is not affected in retinal vein occlusion, but the disc edema tends to persist chronically (Liu et al., 2001).

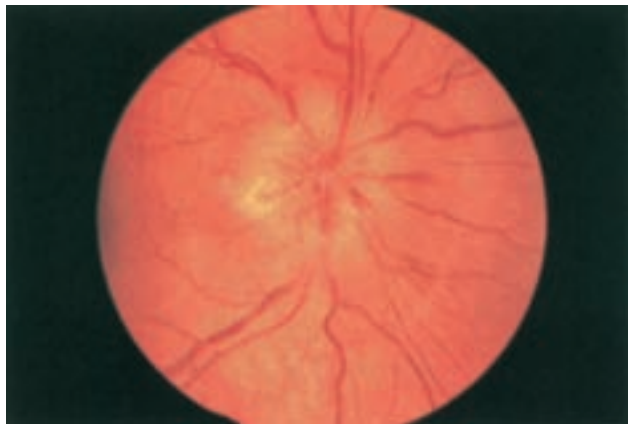Infiltration of the optic nerve is another potential cause of unilateral optic disc edema and can be secondary to carcinomatous, lymphoreticular, or granulomatous processes. One or both optic nerves may be affected. Optic discs may appear swollen or normal, the latter indicating a retrobulbar involvement. Occasionally, optic nerve infiltration produces optic disc edema without affecting visual function, but more often there is a decrease in visual acuity and visual field loss. Almost any form of carcinoma can metastasize to the optic nerve, but breast and lung carcinomas are the most common. Carcinomatous meningitis is a fairly common associated feature. Primary optic nerve neoplasms include the juvenile, benign, pilocytic astrocytoma, which often is associated with neurofibromatosis type 1. Patching of the unaffected eye is necessary to avoid amblyopia. Clinical or radiographic progression constitutes grounds for more



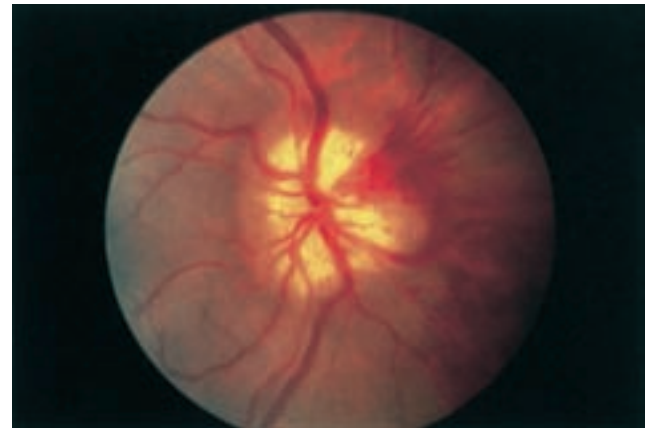
**FIGURE 15-6** Optic disc edema and hyperemia from central retinal vein occlusion in a 55-year-old woman. (Reprinted with permission from Beck, R. W., & Smith, C. H. 1988, *Neuro-Ophthalmology: A Problem-Oriented Approach*, Little, Brown, Boston.)

aggressive treatment, with chemotherapy, radiation therapy, or rarely surgery. The malignant optic nerve glioblastoma is much rarer, affects adults, and carries a considerably worse prognosis. Survival is limited to several months. Meningiomas of the optic nerve sheath occur primarily in women and can cause acuity loss associated with either disc swelling or atrophy; if symptoms worsen, local irradiation may be indicated. Sarcoidosis involving the optic nerve produces a characteristic disc appearance, including disc edema and whitish nodules on the disc surface (Fig. 15-7) (Liu et al., 2001).

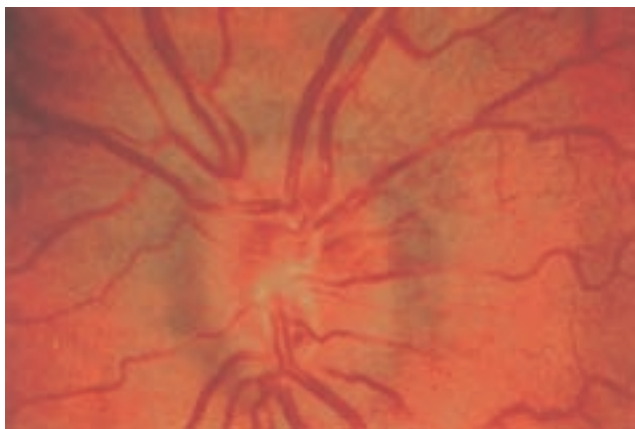
Optic neuropathy as a delayed effect of radiation therapy can occur with or without disc edema. When this rare complication occurs, it usually follows the radiation regimen by 6 to 24 months. Progression occurs over weeks to months, and spontaneous recovery is rare. Steroids may help by reducing edema in the affected optic nerve.



**FIGURE 15-5** Papillophlebitis in a 23-year-old woman. (Reprinted with permission from Beck, R. W., & Smith, C. H. 1988, *Neuro-Ophthalmology: A Problem-Oriented Approach*, Little, Brown, Boston.)



**FIGURE 15-7** Optic disc swelling, hemorrhage, and infiltration, due to sarcoidosis, in a 30-year-old man. (Reprinted with permission from Beck, R. W., & Smith, C. H. 1988, *Neuro-Ophthalmology: A Problem-Oriented Approach*, Little, Brown, Boston.)



**FIGURE 15-8** Hyperemic disc, with telangiectatic vessels in the peripapillary nerve fiber layer, in a 26-year-old man with Leber's hereditary optic neuropathy. (Reprinted with permission from Beck, R. W., & Smith, C. H. 1988, *Neuro-Ophthalmology: A Problem-Oriented Approach*, Little, Brown, Boston.)

Leber's hereditary optic neuropathy (LHON) is an uncommon subacute, sequential, maternally inherited optic nerve disorder in which 80% to 90% of affected persons are males in the second or third decade of life (see Chapter 14). Although there is not true disc edema in LHON, the optic disc may appear hyperemic and mildly swollen in the acute phase (Fig. 15-8). Circumpapillary telangiectatic vessels, frequently present in the peripapillary nerve fiber layer, are an important clue to the diagnosis. These early fundusoscopic changes also may be noted in presymptomatic eyes. Thus, although a patient may present with symptoms of involvement of only one eye, LHON may be suspected on the basis of characteristic disc changes in both eyes. As the condition progresses, the discs become atrophic. Fibers mediating the pupillary light reflex may be selectively spared compared with those for vision, so the light reflex may be preserved despite significant visual loss. Genetic diagnosis of LHON is based on the identification of related mitochondrial DNA mutations (see Chapter 67). Some recovery of vision occurs in 4% to 32% of patients, depending on the specific mutation. At present, no effective treatment for this condition is available (Chinnery and Griffiths, 2005).

Other uncommon causes of unilateral optic disc edema are described next, under "Bilateral Optic Disc Edema," which occasionally can have a unilateral presentation.

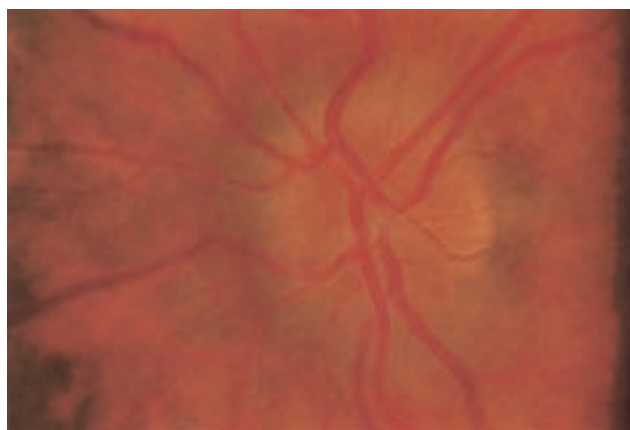
## Bilateral Optic Disc Edema

### *Papilledema*

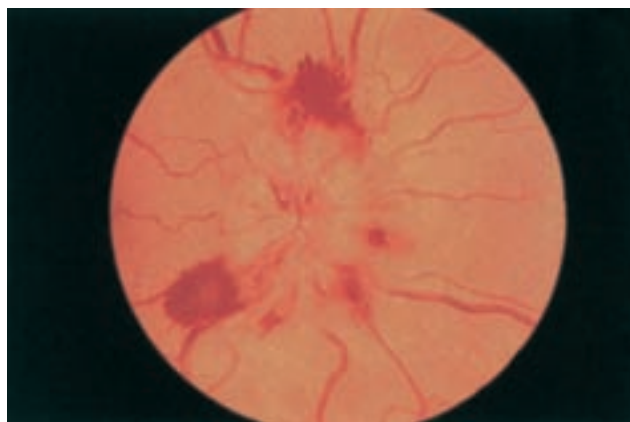
The term *papilledema* refers specifically to optic disc swelling that occurs secondary to increased intracranial pressure. Disc swelling in papilledema results from blockage of axoplasmic flow in nerve fibers, with a consequent increase in the volume of axoplasm in the optic disc. On the basis of the chronicity and fundusoscopic appearance, papilledema can be divided into four stages: early, fully developed (acute), chronic, and atrophic. The acute phase of papilledema is strongly suggested by a markedly swollen disc and relatively spared optic nerve function, particularly central visual acuity. The most

common visual field defects encountered in patients with early or acute papilledema are enlargement of the physiologic blind spot, concentric constriction, and inferior nasal field loss.

In early papilledema, swelling is most prominent at the superior and inferior poles of the optic disc, where the nerve fiber layer is thickest (Fig. 15-9). With further development of papilledema, swelling encompasses the disc surface more uniformly, and the degree of disc elevation increases. The retinal veins may be slightly distended, and the disc may appear mildly hyperemic. These vascular changes result from nerve fiber swelling causing compression of capillaries and venules, leading to venous stasis and dilation, the formation of microaneurysms, and finally disc and peripapillary splinter hemorrhages (Fig. 15-10). Correspondingly, in fluorescein angiography, fluorescence may be absent during the retinal arterial phase as a result of delayed circulation caused by disc swelling; dilated capillaries, microaneurysms, and flame-shaped hemorrhages may appear in the arteriovenous phase; and fluorescein may



**FIGURE 15-9** Swollen optic disc in early papilledema. Note that this swelling is more prominent superiorly and inferiorly than temporally. (Reprinted with permission from Beck, R. W., & Smith, C. H. 1988, *Neuro-Ophthalmology: A Problem-Oriented Approach*, Little, Brown, Boston.)



**FIGURE 15-10** Disc edema and hemorrhages in acute (fully developed) papilledema. (Reprinted with permission from Beck, R. W., & Smith, C. H. 1988, *Neuro-Ophthalmology: A Problem-Oriented Approach*, Little, Brown, Boston.)

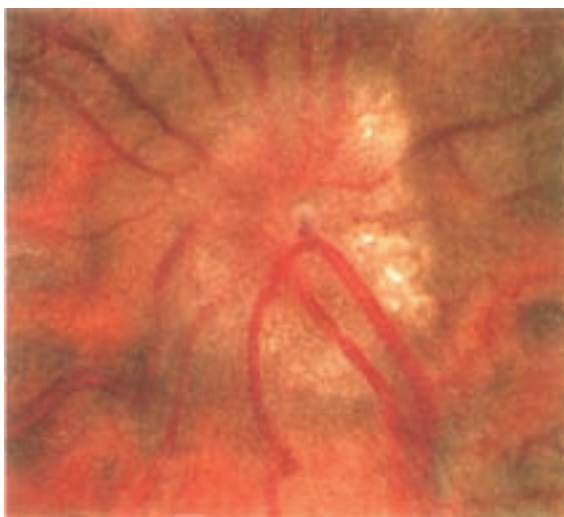
leak from dilated capillaries in the venous phase. Retinal cotton wool spots are common and represent areas of ischemia in the nerve fiber layer. Spontaneous venous pulsations usually are absent once the intracranial pressure exceeds 18 cm H<sub>2</sub>O. Although papilledema typically is bilateral, it can be asymmetrical because of differences in transmitted pressure related to anatomical variation in the meningeal covering of the intracranial and the intracanalicular optic nerves.

As papilledema becomes chronic, usually after weeks to months, the disc appearance changes. The nerve fiber layer may appear pale and take on a gliotic appearance, as a result of optic atrophy and astrocytic proliferation. Hemorrhages are less prominent (and often have resolved completely). The disc takes on a “champagne cork” appearance, in which small glistening white bodies (pseudodrusen) result from extruded axoplasm after prolonged stasis (Fig. 15-11). Shunt vessels from the retinal to ciliary circulation appear, which result from compensatory dilation of preexisting communications, in the setting of decreased flow through the central retinal vein (Fig. 15-12).

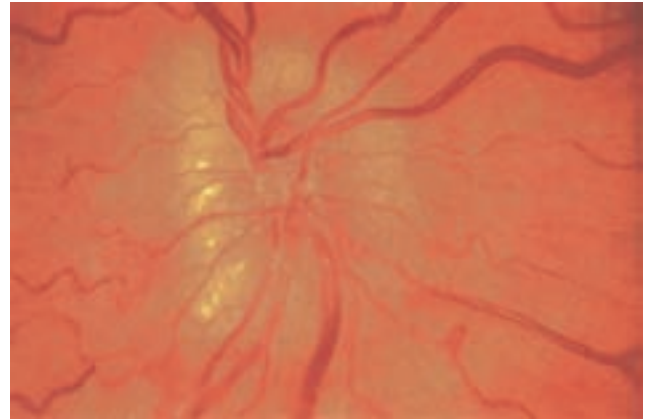
If increased intracranial pressure and papilledema persist, optic nerve axons become damaged, and visual field loss develops. At this stage, optic disc swelling lessens, and pallor develops (atrophic papilledema) (Fig. 15-13). Finally, patients with end-stage papilledema exhibit optic nerve atrophy (disc pallor), without evidence of swelling. Chronic and atrophic papilledema, unlike in the early and acute phases, often are characterized by loss of visual acuity and visual fields.

When acute papilledema is accompanied by decreased acuity (and possible metamorphopsia), the cause typically is extension of fluid within the nerve fiber layer, reaching the macula itself. After treatment for elevated intracranial pressure, a circumpapillary “high-water mark” may identify the prior extent of retinal elevation caused by disc swelling.

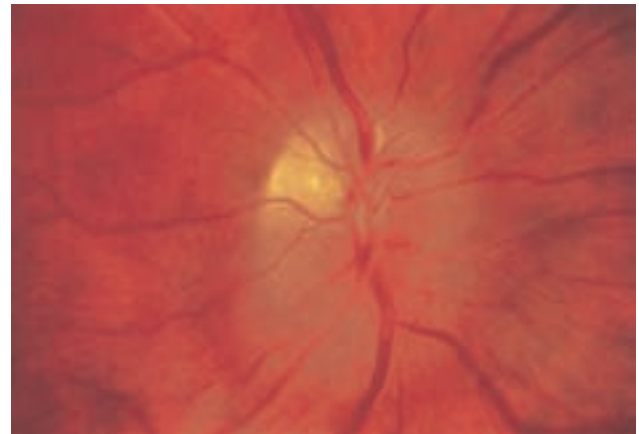
Papilledema due to increased intracranial pressure can be the consequence of numerous processes. An expanding mass lesion, such as a brain tumor, is more likely to cause papilledema



**FIGURE 15-11** Chronic papilledema with marked disc elevation and gliotic appearance to the disc surface. Note that hemorrhages are not present. (Reprinted with permission from Beck, R. W., & Smith, C. H. 1998. *Neuro-Ophthalmology: A Problem-Oriented Approach*, Little, Brown, Boston.)



**FIGURE 15-12** Chronic papilledema with glistening white bodies called pseudodrusen. (Reprinted with permission from Beck, R. W., & Smith, C. H. 1988. *Neuro-Ophthalmology: A Problem-Oriented Approach*, Little, Brown, Boston.)



**FIGURE 15-13** Chronic papilledema with optic nerve atrophy. Note that the superior portion of the optic disc is pale and not swollen—a result of damaged axons. (Reprinted with permission from Beck, R. W., & Smith, C. H. 1988. *Neuro-Ophthalmology: A Problem-Oriented Approach*, Little, Brown, Boston.)

in a younger patient, in whom intracranial pressure will rise more rapidly in the absence of age-related brain atrophy. Compression of the ventricular system in the posterior fossa is particularly likely to cause papilledema. Ischemic stroke with subsequent cerebral edema, intracerebral hemorrhage, and epidural and subdural hematomas all are possible causes. Venous sinus thrombosis is common, particularly in pregnancy and other states of hypercoagulability, and causes elevated intracranial pressure and papilledema. Cryptococcal meningitis is the infectious etiologic disorder most commonly associated with significant papilledema and necessitates antifungal therapy. Pseudotumor cerebri, or idiopathic intracranial hypertension, can lead to disc swelling and progressive visual loss from field constriction. The condition is most common in obese women and also may be associated with the use of tetracycline or vitamin A. Weight loss is imperative, and in cases of visual loss,

treatment with acetazolamide, followed by optic nerve sheath fenestration in refractory cases, may be indicated.

### ***Malignant Hypertension***

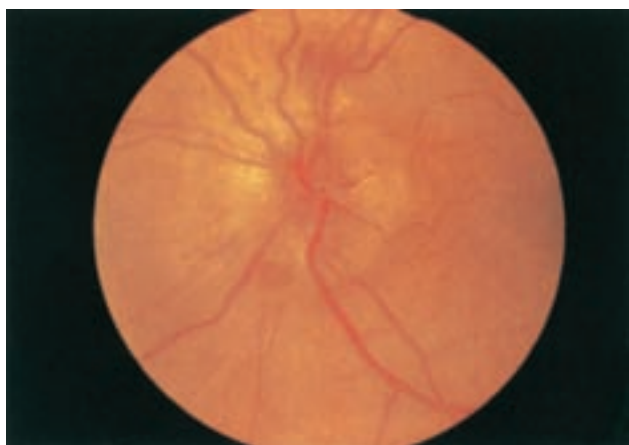A marked elevation in blood pressure may produce bilateral optic disc swelling that is indistinguishable from papilledema (Fig. 15-14). Peripapillary cotton wool spots also are a prominent funduscopic feature in patients with malignant hypertension. Encephalopathic signs are common but not always present. Disc edema tends to develop at a lower blood pressure in patients with renal failure than in those without renal disease.

### ***Diabetic Papillopathy***

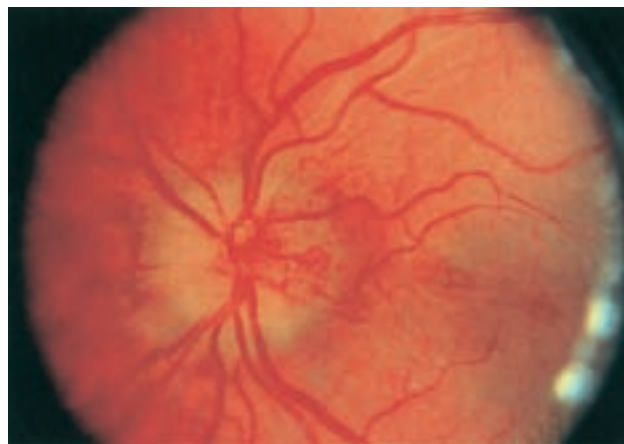
Diabetic papillopathy is a rare cause of bilateral (or sometimes unilateral) disc swelling in patients with type 1 diabetes. This entity is distinct from AION in that there is often bilateral, simultaneous optic nerve involvement. Often no visual field loss occurs, with the exception of an enlarged physiological blind spot, and only a mild deficit in acuity is noted. Disc edema is accompanied by marked capillary telangiectasias overlying the disc surface (Fig. 15-15). Measurement of cerebrospinal fluid pressure (after neuroimaging to rule out intracranial mass lesions or venous sinus thrombosis) may be necessary to distinguish this condition from papilledema. The pathogenesis is unclear but may relate to impairment of blood flow causing disc swelling, but not of sufficient degree to significantly affect optic nerve function. In many cases, the optic disc edema resolves without residual visual deficit (Barbera et al., 1996).

### ***Other Causes***

Anemia, hyperviscosity syndromes, pickwickian syndrome, hypotension, and severe blood loss are less common causes of bilateral optic disc swelling. The clinical setting generally provides clues to the diagnosis. In addition, any of the entities



**FIGURE 15-14** Swollen optic disc in a patient with malignant hypertension. The disc in the fellow eye had a similar appearance. (Reprinted with permission from Beck, R. W., & Smith, C. H. 1988, *Neuro-Ophthalmology: A Problem-Oriented Approach*, Little, Brown, Boston.)

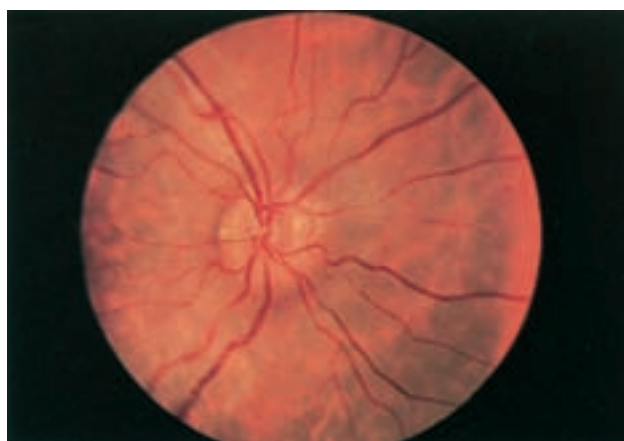

**FIGURE 15-15** Diabetic papillopathy in a 17-year-old girl. Note the telangiectatic vessels on the disc surface. (Reprinted with permission from Beck, R. W., & Smith, C. H. 1988, *Neuro-Ophthalmology: A Problem-Oriented Approach*, Little, Brown, Boston.)

described under unilateral optic disc edema, particularly the infiltrative disorders (see Table 15-1), rarely can cause bilateral disc swelling. In children, optic neuritis commonly is bilateral and often is associated with bilateral papillitis (disc swelling). Bilateral AION should prompt immediate evaluation for giant cell (temporal) arteritis in patients older than 55 years. Although most toxic optic neuropathies manifest with normal-appearing optic discs, disc edema is characteristic of methanol poisoning and also may occur in patients with ethambutol toxicity.

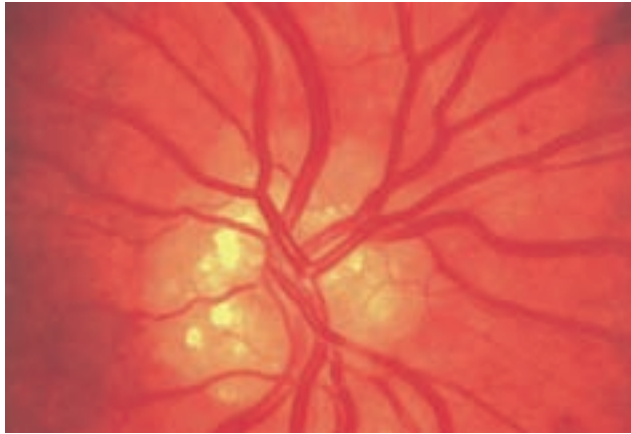
### ***Pseudopapilledema***

In patients with pseudopapilledema, visible optic disc drusen (hyaline bodies) may be present (Figs. 15-16 and 15-17). Even



**FIGURE 15-16** Pseudopapilledema in a 14-year-old boy. Although the disc margins are blurred, the nerve layer appears clear. No drusen are evident on the surface. The fellow eye appeared similar. (Reprinted with permission from Beck, R. W., & Smith, C. H. 1988, *Neuro-Ophthalmology: A Problem-Oriented Approach*, Little, Brown, Boston.)





**FIGURE 15-17** Optic disc drusen in a 50-year-old man. (Reprinted with permission from Beck, R. W., & Smith, C. H. 1988, *Neuro-Ophthalmology: A Problem-Oriented Approach*, Little, Brown, Boston.)

when disc drusen are not apparent, the distinction between true disc swelling and pseudopapilledema almost always can be made on the basis of ophthalmoscopic findings (Table 15-2). The most important distinguishing feature is the clarity of the peripapillary nerve fiber layer. In patients with true disc edema, the nerve fiber layer is hazy, obscuring the underlying retinal vessels, whereas in pseudopapilledema, this layer can remain distinct. In addition, the presence of spontaneous venous pulsations (SVPs) supports the diagnosis of pseudopapilledema, although SVP can be absent in pseudopapilledema as well. Hemorrhages may be present in patients with pseudopapilledema (particularly in the setting of optic disc drusen) and therefore do not exclude this possibility. Splinter hemorrhages, however, are more characteristic of true papilledema, whereas peripapillary subretinal hemorrhages often signify pseudopapilledema. Finally, fluorescein angiography will show leakage from vessels in papilledema, which is not seen in pseudopapilledema (Davis and Jay, 2003).

**Optic Disc Drusen**

Optic disc drusen constitute a common cause of pseudopapilledema; these bodies are thought to be calcium deposits within the optic nerve head related to axonal degeneration from altered

axoplasmic flow. In children, disc drusen tend to be buried, whereas in adults, they often are visible on the disc surface. The progression from buried to surface drusen in individual patients has been well documented. The prevalence of optic disc drusen is approximately 2% within the general population, and they can be bilateral in two thirds of cases. Optic disc drusen are much more common in white patients than in African Americans and may be inherited in an autosomal dominant pattern with incomplete penetrance.

Patients with optic disc drusen generally do not complain of visual symptoms, although rarely a patient may experience transient visual obscurations similar to those described by patients with true papilledema. Although patients may be unaware of a visual field defect, such deficits are common, occurring in approximately 70% of eyes with visible disc drusen and in 35% of those with pseudopapilledema but no visible drusen. The scotoma probably results from nerve fiber layer thinning and axonal dysfunction caused by the drusen. The visual field defects, therefore, generally follow a nerve fiber bundle distribution, with inferior nasal visual field loss being the most common. Enlargement of the blind spot and generalized field constriction also may occur. Progression of visual field defects in the setting of drusen is well documented. In addition, visual field loss in the setting of optic disc drusen may occur secondary to hemorrhage, superimposed ischemic optic neuropathy, or an associated retinal degeneration. Visual acuity loss associated with drusen is rare, however, and should prompt an evaluation for alternative causes.

**OPTIC NEUROPATHIES WITH NORMAL-APPEARING OPTIC DISCS**

Many optic neuropathies manifest initially with a completely normal disc appearance; these are classified as retrobulbar optic neuropathies. The disc appearance is normal because the pathological process is posterior to the lamina cribrosa. As with the swollen disc, the differential diagnosis depends on whether unilateral or bilateral optic nerve involvement is present (see Table 15-1).

**Unilateral Presentations**

The most common causes of unilateral retrobulbar optic neuropathy are acute demyelinating optic neuritis and compressive

**TABLE 15-2** Differentiation of Early Papilledema and Pseudopapilledema

FEATURE	PAPILLEDEMA	PSEUDOPAPILLEDEMA
Disc color	Hyperemic	Pink, yellowish pink
Disc margins	Indistinct early at superior and inferior poles, later entire margin	Irregularly blurred, may be lumpy
Disc elevation	Minimal	Minimal to marked; center of disc most elevated
Vessels	Normal distribution, slight fullness; spontaneous venous pulsations absent	Emanate from center, frequent anomalous pattern, ± spontaneous venous pulsations
Nerve fiber layer	Dull as a result of edema, which may obscure blood vessels	No edema; may glisten with circumpapillary halo of feathery light reflections
Hemorrhages	Splinter	Subretinal, retinal, vitreous

Reprinted with permission from Beck, R. W., & Smith, C. H. 1988, *Neuro-Ophthalmology: A Problem-Oriented Approach*, Little, Brown, Boston.

lesions. The time course of vision loss usually is helpful in distinguishing between these two entities. There is no definite way to differentiate these disorders on examination, but the detection of a superior temporal field defect in the fellow eye (a junctional scotoma) is highly suggestive of a compressive lesion affecting the anterior optic chiasm and the posterior optic nerve, involving the decussating fibers (termed *Willebrand's knee* or *genu*). Retrobulbar ischemic optic neuropathy is a rare condition seen in patients with giant cell arteritis or with other vasculitides, and after shock or severe blood loss. For practical purposes, there is no retrobulbar correlate to nonarteritic AION.

## Bilateral Presentations

Bilateral optic neuropathies in which the optic discs appear normal include nutritional optic neuropathy (including tobacco-alcohol amblyopia), vitamin B<sub>12</sub> or folate deficiencies, toxic optic neuropathy (from heavy metals), drug-related optic neuropathy (due to chloramphenicol, isoniazid, ethambutol, ethchlorvynol, chlorpropamide, and others), and inherited optic neuropathies. When these conditions are chronic, optic atrophy may ensue. Other diagnostic considerations in this category include bilateral compressive lesions and bilateral retrobulbar optic neuritis. Finally, posterior indirect traumatic optic neuropathy can result from shearing forces and subsequent edema within the optic canal.

## OPTIC NEUROPATHIES WITH OPTIC ATROPHY

Any optic neuropathy that produces damage to the optic nerve may result in optic atrophy. Compressive lesions characteristically will cause progressive visual loss and optic atrophy. For the most part, however, optic atrophy alone is rarely helpful in determining the underlying cause. The presence of gliotic changes suggests that the disc was previously swollen. Deep disc cupping is typical of glaucoma but also is common after AION as a result of giant cell arteritis. Dominantly inherited optic atrophy often is associated with a characteristic disc appearance, with pallor and excavation of the temporal portion of the disc. Rarely, disc cupping develops in the setting of intracranial lesions that cause nerve compression.

Optic atrophy also occurs as a consequence of disorders of the retina, optic chiasm, and optic tract. In patients with optic tract lesions, a specific pattern of disc pallor termed “bow-tie atrophy,” which is characterized by temporal pallor of the ipsilateral disc and both nasal and temporal pallor of disc contralateral to the lesion, is seen. Acquired geniculocalcarine lesions (posterior to the optic tract) do not produce disc pallor, although congenital lesions in this area may do so.

## CONGENITAL OPTIC DISC ANOMALIES

Congenital optic nerve anomalies (in addition to optic disc drusen, as discussed earlier in this chapter) include a tilted optic

disc and optic nerve dysplasia. Visual loss associated with a congenital disc anomaly can range from total blindness to minimal dysfunction. Children can present with strabismus if there is significant unilateral visual loss, or nystagmus in cases of bilateral visual loss.

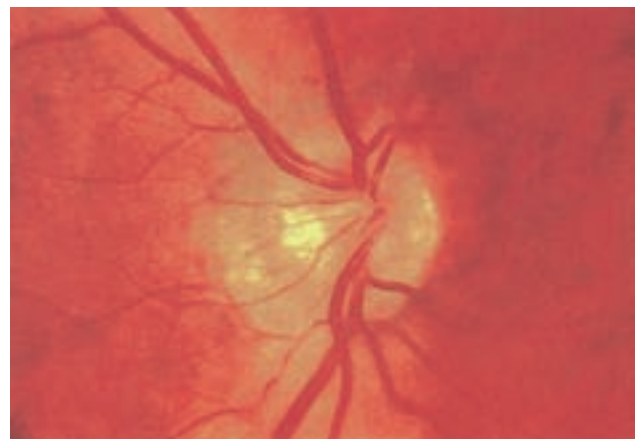
## Tilted Optic Disc

A tilted optic disc usually is easily recognized on ophthalmoscopy. The disc may appear foreshortened on one side, and one portion may appear elevated with the opposite end depressed (Fig. 15-18). Often, the retinal vessels run in an oblique direction. Tilted optic discs are of neurological importance in that they usually are bilateral and may be associated with temporal field loss, thus mimicking a chiasmal syndrome. However, differentiation from chiasmal disease generally is possible because visual field defects in patients with tilted discs generally do not respect the vertical meridian.

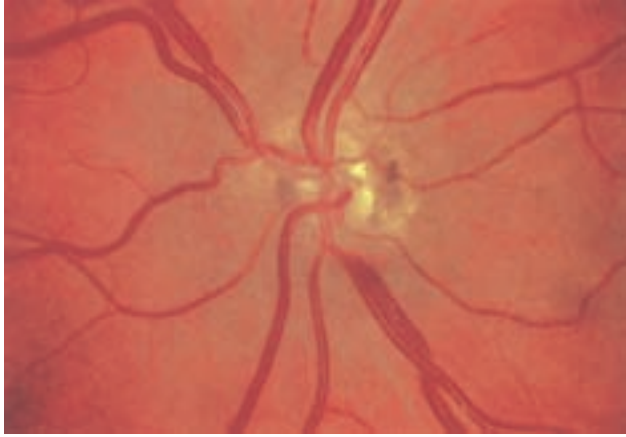
## Optic Nerve Dysplasia

Of the several types of optic nerve dysplasia, optic nerve hypoplasia is the most common. In this condition, the optic disc appears small, and the nerve substance is surrounded by choroid and retinal pigment changes that resemble a double ring (Fig. 15-19). The abnormality may be unilateral or bilateral. In most cases, a specific cause cannot be identified. The frequency of optic nerve hypoplasia appears to be increased in children of mothers with diabetes mellitus or who ingested antiepileptic drugs, quinine, or lysergic acid diethylamide (LSD) during pregnancy. De Morsier's syndrome (septo-optic dysplasia) is characterized by developmental abnormalities of structures sharing an embryological forebrain derivation, including bilateral optic nerve hypoplasia, absent septum pellucidum, and pituitary gland dysfunction (classic growth hormone deficiency). Optic nerve aplasia, or complete absence of the optic discs, is extremely rare.

Optic nerve coloboma is more common than optic nerve hypoplasia and results from incomplete closure of the fetal



**FIGURE 15-18** Tilted optic disc. The disc in the fellow eye had a similar appearance.



**FIGURE 15-19** Optic nerve hypoplasia. (Reprinted with permission from Beck, R. W., & Smith, C. H. 1988, *Neuro-Ophthalmology: A Problem-Oriented Approach*, Little, Brown, Boston.)

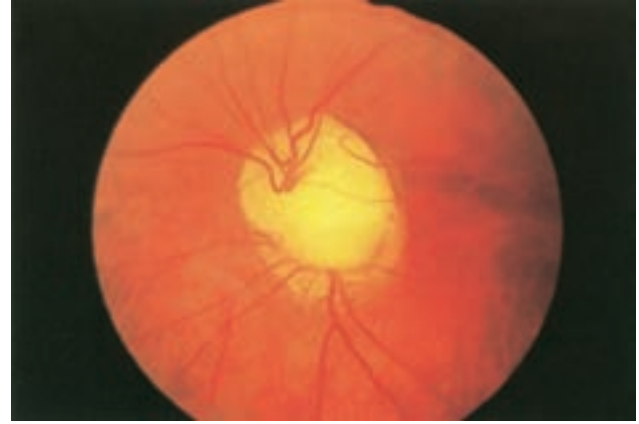fissure (Fig. 15-20). It may occur as an isolated finding or as part of a congenital syndrome, including Aicardi's syndrome, trisomy 13, and Goldenhar's syndrome. Another type of congenital anomaly, the optic pit, is manifested as a small grayish area, usually located in the inferior temporal portion of the optic disc.

In some optic nerve dysplasias, the disc appears enlarged. This is true of the so-called "morning glory disc", in which a large whitish concavity is surrounded by pigmentation that resembles a morning glory flower. The anomaly also may be caused by defective closure of the embryonic fissure, with the enlarged disc becoming filled with glial tissue and vascular remnants. This condition may be associated with other developmental anomalies, such as a basal encephalocele.

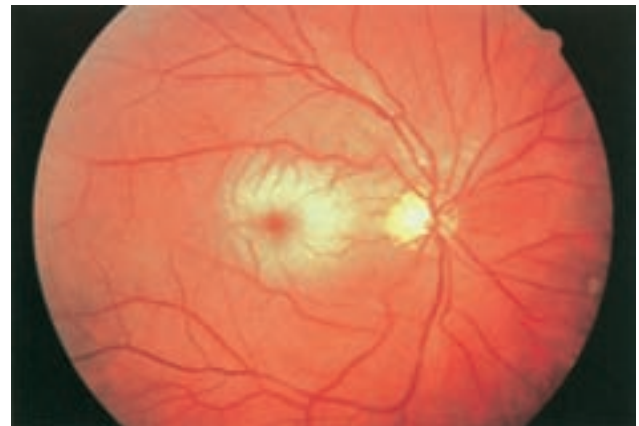## RETINAL DISORDERS

### Retinal Arterial Disease

Retinal arterial disease can manifest as a central retinal artery occlusion or branch retinal artery occlusion (CRAO/BRAO), or as amaurosis fugax (transient monocular visual loss). Carotid artery atherosclerotic disease is the most common cause; cardiac valvular disease also must be considered. The evaluation and treatment for retinal arterial disease are similar to those for stroke and cerebrovascular disease in general, because the annual risk of stroke or death in patients with visible retinal emboli can be increased 10-fold to 8.5%, compared with controls (Petty et al., 1998). Acute retinal artery occlusion (CRAO/BRAO) is characterized by retinal whitening (edema) secondary to infarction. In CRAO, these findings usually are more prominent in the posterior pole than they are in the periphery (Fig. 15-21). A marked narrowing of the retinal arterioles often is noted. Because the fovea (the center of the macula) receives its blood supply from the choroid and there are no overlying retinal ganglion cells, this area retains its normal reddish-orange color, producing the character-



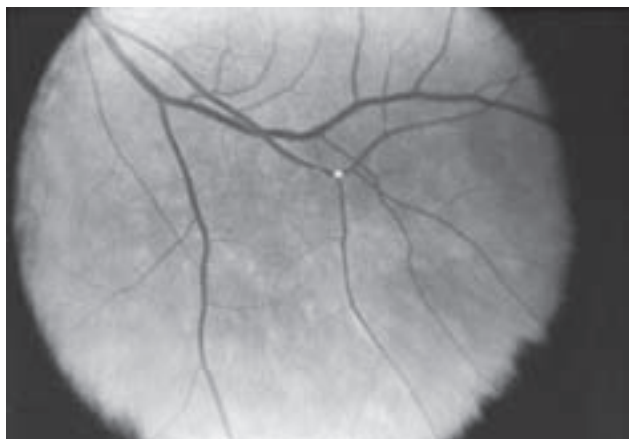
**FIGURE 15-20** Optic disc coloboma. (Reprinted with permission from Beck, R. W., & Smith, C. H. 1988, *Neuro-Ophthalmology: A Problem-Oriented Approach*, Little, Brown, Boston.)



**FIGURE 15-21** Central retinal artery occlusion. Note the cherry-red spot in the center of the macula, with surrounding whitening of the retina.

istic cherry-red spot. The retinal edema usually subsides fairly rapidly over days to weeks. After resolution, the retinal appearance typically returns to normal, although the prognosis for visual recovery generally is poor.

When present, retinal emboli most often are located at arteriolar bifurcations (Fig. 15-22). Retinal emboli are visualized more commonly in BRAO than in CRAO. They take on a glistening or whitish or yellowish appearance and may be located on or near the optic disc or in the retinal periphery. The three major types of retinal emboli are (1) cholesterol (Hollenhorst plaques, most commonly from the carotid artery); (2) platelet-fibrin (most commonly from the cardiac valves); and (3) calcific (from either a carotid or cardiac source). It is difficult to accurately distinguish among these on the basis of funduscopy alone. With impaired blood flow after a CRAO, a portion of a retinal arteriole may take on a whitish appearance. This represents not an embolus but, rather, stagnant lipid in the blood or changes in the arteriole wall.



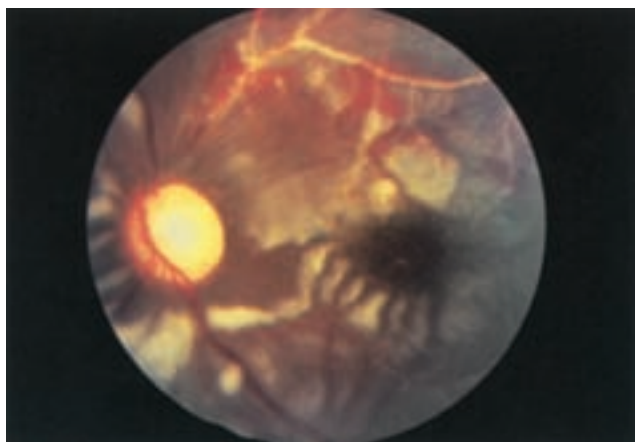
**FIGURE 15-22** Hollenhorst plaque at a retinal arteriole bifurcation. (Reprinted with permission from Beck, R. W., & Smith, C. H. 1988, *Neuro-Ophthalmology: A Problem-Oriented Approach*, Little, Brown, Boston.)

### Vasculitis

In vasculitis, focal areas of retinal infarction develop. These areas, known as cotton wool spots, usually are bilateral and may be extensive (Fig. 15-23).

### Branch Retinal Artery Occlusions and Encephalopathy (Susac's Syndrome)

Branch retinal artery occlusions and encephalopathy (Susac's syndrome) is a rare disorder of unknown etiology characterized by multiple branch retinal artery occlusions and neurological dysfunction. Susac's syndrome most commonly affects women between the ages of 20 and 40 years. A viral syndrome may precede the development of ocular and neurological signs. The most prominent neurological manifestations are impaired mentation and sensorineural hearing loss. Cerebrospinal fluid in patients with Susac's syndrome shows a mild lymphocytic pleocytosis and elevated protein. Antinuclear antibody (ANA) testing



**FIGURE 15-23** Multiple cotton wool spots in a patient with systemic lupus erythematosus.

and cerebral arteriography are generally normal, but brain magnetic resonance imaging (MRI) most often demonstrates multiple areas of high signal intensity on T2-weighted images that resemble demyelinating plaques (Gross and Eliashar, 2005).

### Ocular Ischemic Syndrome

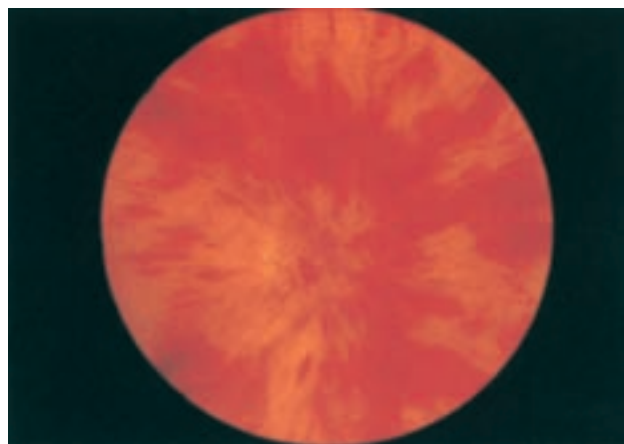
Generalized ocular ischemia indicates involvement of both retinal and ciliary circulations in the eye. Signs of optic nerve and retinal ischemia may be present, as well as ophthalmoplegia and evidence of anterior segment ischemia (iris atrophy, loss of pupil reactivity, cataract formation, rubeosis iridis). Carotid artery occlusion or dissection and giant cell arteritis are the primary considerations in patients with ocular ischemia.

### Retinal Vein Occlusion

Central or branch retinal vein occlusions rarely occur in patients younger than 50 years. The diagnosis is established clinically by the presence of characteristic retinal hemorrhages in the setting of acute vision loss. These occur diffusely in central retinal vein occlusion, and focally in branch retinal vein occlusion (Fig. 15-24). Disc edema often is present and, in some cases, is the predominant fundoscopic feature (see earlier discussion in "Other Causes" under "Unilateral Optic Disc Edema"). In nonischemic vein occlusion, one half of the patients will recover without significant visual loss, and 20% will go on to have complete occlusion. In ischemic occlusion, treatment with panretinal photocoagulation can improve prognosis. No direct associations between retinal vein occlusion and carotid artery atherosclerotic disease are recognized. Patients should be evaluated for vascular risk factors, but carotid imaging or ultrasound examination generally is not indicated. In cases of bilateral retinal vein occlusion, the patient should be evaluated for hyperviscosity syndromes or hypercoagulable states.

### Retinal Degenerations

Among the many diseases of retinal degeneration, several are associated with neurological disease. Retinitis pigmentosa



**FIGURE 15-24** Central retinal vein occlusion.

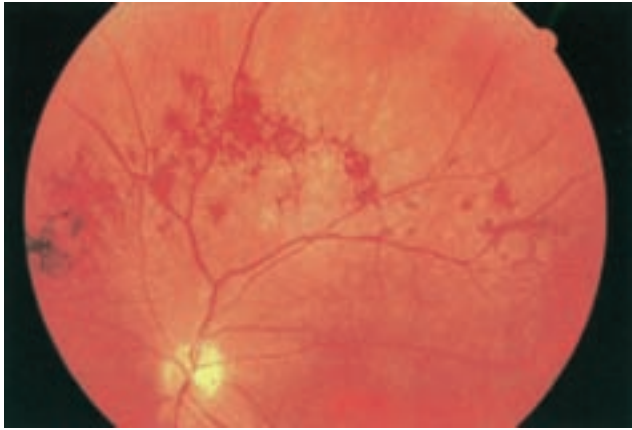

FIGURE 15-25 Retinal findings in retinitis pigmentosa.

(RP) is caused by degeneration of the retinal rods and cones. Early in the course of RP, rods are predominantly affected, thus impairing night vision. Visual field loss occurs first in the mid-periphery and progresses to severe field constriction. Pigmentary changes in the retina look like bony spicules and are the hallmark of RP (Fig. 15-25). In some cases, however, pigment changes are not prominent, and the visual field loss may mistakenly be thought to have a neurological basis. Even without characteristic bony spicule-type changes, the diagnosis of RP can be made on the basis of the retinal thinning, narrowing of retinal arterioles, and waxy optic disc pallor. Regardless of the degree of pigment change, electroretinography is the test of choice for diagnosing RP. RP usually is not accompanied by systemic abnormalities. However, a retinal degeneration of this type may be seen in Kearns-Sayre syndrome, Laurence-Moon-Bardet-Biedl syndrome, Marie’s ataxia, Cockayne’s syndrome, Refsum’s syndrome, Batten’s disease, inherited vitamin E deficiency, and spinocerebellar ataxia type 7.

Retinal photoreceptor degenerations also can occur as a remote effect of cancer (the paraneoplastic retinopathies). These include cancer-associated retinopathy (CAR), which affects primarily rods and manifests with night blindness; cancer-associated cone dysfunction, which manifests as dyschromatopsia; melanoma-associated retinopathy, which has a relatively better prognosis; and others. Visual acuity in these conditions

initially can range from normal to significantly impaired, typically with a rapid rate of deterioration. Arteriolar narrowing is a consistent finding, but pigmentary changes in the retina are variable. Electroretinography is markedly abnormal (showing reduced to extinguished rod and cone components), and antiphotoreceptor antibodies often can be identified in the serum. Treatment of the underlying malignancy typically does not improve vision, but immunosuppression with steroids can be effective.

Progressive cone dystrophies are retinal degenerations occurring most commonly through autosomal dominant inheritance. Typically, vision loss develops in both eyes beginning in adolescence and worsens over several years. Early in the course of cone dystrophy, the fundus may appear normal; with time, however, pigmentary changes develop in the macula, and electroretinography demonstrates characteristic losses of the photopic response.

### Uveoretinal Meningoencephalitis Syndromes

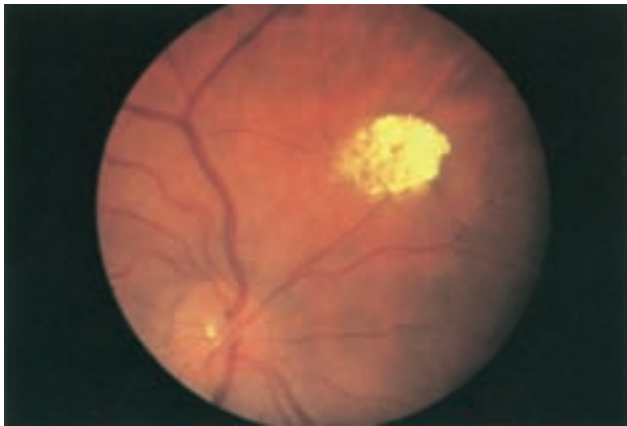
Uveoretinal meningoencephalitis syndromes produce inflammatory changes in both the eye and the central nervous system. Vogt-Koyanagi-Harada syndrome, the most common uveo-meningoencephalitis syndrome, is a T-cell-related disorder, which involves several organ systems, including the eye, skin, and meninges (Andreoli and Foster, 2006). A fluke-like syndrome lasting several weeks typically precedes the ocular symptoms of uveitis and exudative retinal detachment. The retina become depigmented, as well as the skin and hair. Glaucoma is common. Treatment with steroids is of some benefit. Table 15-3 lists causes of ocular and central nervous system inflammation.

### Phakomatoses

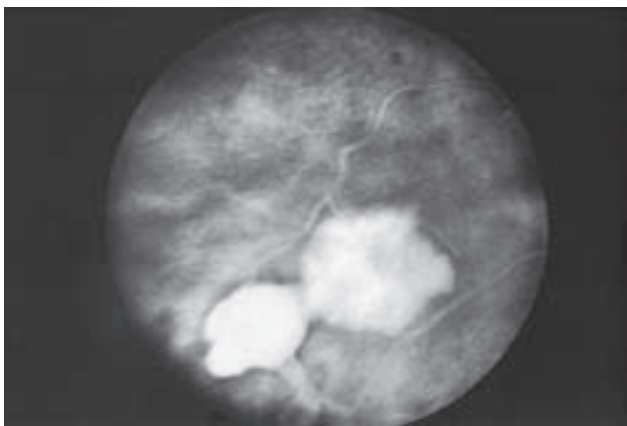
Retinal findings are common in phakomatoses that affect the nervous system, particularly tuberous sclerosis and von Hippel-Lindau disease. Neurological features of phakomatoses are described in Chapter 69. In tuberous sclerosis, retinal astrocytic hamartomas are characteristic (Fig. 15-26). These usually are multiple and may appear either as a fullness in the retinal nerve fiber layer or as a nodular refractile lesion (mulberry type). Von Hippel-Lindau disease is characterized by the presence of one or more retinal angiomas that appear as reddish masses with a

TABLE 15-3 Causes of Uveoretinal Meningoencephalitis Syndromes

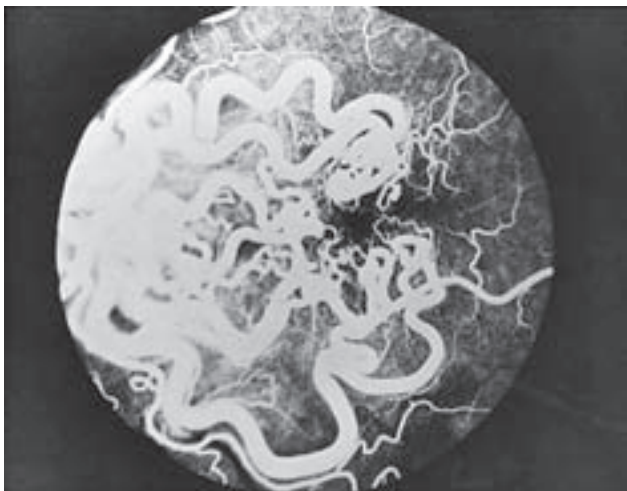
INFECTIOUS INFLAMMATORY	TORY	MALIGNANT
Syphilis	Vogt-Koyanagi-Harada syndrome	Reticulum cell sarcoma
Fungus Sarcoidosis		Lymphoma
Tuberculosis	Multiple sclerosis	Leukemia
Cytomegalovirus	Behçet’s disease	Metastatic carcinoma
Herpes simplex	Systemic lupus erythematosus	
Herpes zoster	Inflammatory bowel disease	
Subacute sclerosing panencephalitis	Acute posterior multifocal placoid pigment epitheliopathy	
Miscellaneous infections		
Toxoplasmosis		
Whipple’s disease		
Acquired immunodeficiency syndrome		



**FIGURE 15-26** Astrocytic hamartoma in a patient with tuberous sclerosis.



**FIGURE 15-27** Retinal angioma in a patient with von Hippel-Lindau disease.



**FIGURE 15-28** Fluorescein angiogram of a racemose arteriovenous malformation in the retina in a patient with Wyburn-Mason disease.

feeding artery and a draining vein (Fig. 15-27). Treatment with photocoagulation or cryotherapy may be necessary. Wyburn-Mason disease is characterized by racemose arteriovenous malformations in the retina (Fig. 15-28).

## References

- Andreoli, C. M., & Foster, C. S. 2006, Vogt-Koyanagi-Harada disease, *Int Ophthalmol Clin* 2006; 46(2): 111-122.
- Arnold, A. C. 2003, Pathogenesis of nonarteritic anterior ischemic optic neuropathy. *J Neuroophthalmol*, vol. 23, pp. 157-163
- Arnold, A. C., & Levin, L. A. 2002, Treatment of ischemic optic neuropathy, *Semin Ophthalmol*, vol. 17, pp. 39-46
- Baier, M. L., Cutter, G. R., Rudick, R. A., et al. 2005, Low-contrast letter acuity testing captures visual dysfunction in patients with multiple sclerosis, *Neurology*, vol. 64, pp. 992-995
- Balcer, L. J. 2001, Anatomical review and topographic diagnosis, *Ophthalmol Clin North Am*, vol. 14, pp. 1-21, vii
- Balcer, L. J. 2006, Clinical practice. Optic neuritis, *N Engl J Med*, vol. 354, pp. 1273-1280
- Balcer, L. J., & Beck, R. W. 2003, Inflammatory optic neuropathies and neuroretinitis, in *Ophthalmology*, 2nd ed., edited by M. Yanoff & M. Duker, Mosby, St. Louis
- Balcer, L. J., & Galetta, S. L. 2003, Optic neuropathies, in *Neurological Therapeutics: Principles and Practice*, edited by J. H. Noseworthy, Martin Dunitz, London
- Barbera, L. G., Weiss, M. J., & Hofeldt, A. J. 1996, Diabetic retinopathy and diabetic papillopathy, *Semin Neurol*, vol. 16, pp. 179-185
- Beck, R. W. 1998, Optic neuritis, in *Walsh and Hoyt's Clinical Neuro-Ophthalmology*, 5th ed., edited by N. R. Miller & N. J. Newman, Williams & Wilkins, Baltimore
- Beck, R. W., Gal, R. L., Bhatti, M. T., et al. 2004, Visual function more than 10 years after optic neuritis: experience of the Optic Neuritis Treatment Trial, *Am J Ophthalmol*, vol. 137, pp. 77-83
- Beck, R. W., Trobe, J. D., Moke, P. S., et al. 2003, High- and low-risk profiles for the development of multiple sclerosis within 10 years after optic neuritis: experience of the Optic Neuritis Treatment Trial, *Arch Ophthalmol*, vol. 121, pp. 944-949
- Chang, S. H., & Miller, N. R. 2005, The incidence of vision loss due to perioperative ischemic optic neuropathy associated with spine surgery: the Johns Hopkins Hospital Experience, *Spine*, vol. 30, pp. 1299-1302
- Chinnery, P. F., & Griffiths, P. G. 2005, Optic mitochondriopathies, *Neurology*, vol. 64, pp. 940-941
- Davis, P. L., & Jay, W. M. 2003, Optic nerve head drusen, *Semin Ophthalmol*, vol. 18, pp. 222-242
- Gross, M., & Eliashar, R. 2005, Update on Susac's syndrome, *Curr Opin Neurol*, vol. 18, pp. 311-314
- Hall, J. K., & Balcer, L. J. 2004, Giant cell arteritis, *Curr Treat Options Neurol*, vol. 6, pp. 45-53
- Liu, G. T., Volpe, N. J., & Galetta, S. L. 2001, *Neuro-Ophthalmology: Diagnosis and Management*, WB Saunders, Philadelphia
- Mathews, M. K. 2005, Nonarteritic anterior ischemic optic neuropathy, *Curr Opin Ophthalmol*, vol. 16, pp. 341-345
- Petty, W., Engel, A. G., Young, B. R., et al. 1998, Retinocochleocerebral vasculopathy, *Medicine*, vol. 77, pp. 12-14
- Susac, J. O. 2004, Susac's syndrome, *AJNR Am J Neuroradiol*, vol. 25, pp. 351-352
- Trobe, J. D., Beck, R. W., Moke, P. S., Cleary, P. A. 1996, Contrast sensitivity and other vision tests in the Optic Neuritis Treatment Trial, *Am J Ophthalmol*, vol. 121, pp. 547-553
- Wingerchuk, D. M. 2006, Neuromyelitis optica, *Adv Neurol*, vol. 98, pp. 319-333

A Suggested Reading list for this chapter can be found at [www.nicp.com](http://www.nicp.com).