

**PEDIATRIC NEWBORN
MEDICINE CLINICAL
PRACTICE GUIDELINES**

Diagnostic Evaluation of
Necrotizing Enterocolitis
(NEC)





Clinical Practice Guideline: Diagnostic evaluation of the neonate with established or suspected necrotizing enterocolitis (NEC)

Points of emphasis/Primary changes in practice:

1. Establish and operationalize an abdominal ultrasound protocol specific for necrotizing enterocolitis assessment that can be ordered as part of the diagnostic evaluation of neonates with suspected necrotizing enterocolitis. This imaging exam will be referred to in this document as “**abdominal ultrasound for NEC**”.
2. Establish criteria for ordering and guidelines for reporting results of an abdominal ultrasound for NEC.
3. Implement a clinical practice guideline for the diagnostic evaluation of necrotizing enterocolitis that is inclusive of an abdominal ultrasound for NEC examination.

Rationale for change: To enhance and standardize the diagnostic evaluation of neonates with suspected necrotizing enterocolitis in the BWH NICU with a goal for earlier and more definitive detection of necrotizing enterocolitis, avoiding unnecessary treatment in the absence of necrotizing enterocolitis, and providing additional information to guide decisions regarding the severity of the disease and potential need for surgical intervention.

Questions? Please contact:

Richard Parad MD MPH, rparad@bwh.harvard.edu, 617-732-8405

Judy Estroff MD, judy.estroff@childrens.harvard.edu, 617-355-3447

Catherine Chen MD MPH, catherine.chen@childrens.harvard.edu, 617-355-0535



Clinical Guideline Name	Diagnostic evaluation necrotizing enterocolitis (NEC)
Effective Date	June 19, 2017
Revised Date	
Contact Person	Richard Parad MD MPH <u>Members of the abdominal ultrasound for NEC CPG Working group:</u> <u>Brigham and Women's Hospital:</u> Richard Parad, MD, MPH (Neonatologist) Carol Benson, MD (Director of Ultrasound) NICU Nursing Educators <u>Boston Children's Hospital:</u> Catherine Chen, MD, MPH (Pediatric Surgeon) Judy Estroff MD (Division Chief, Fetal & Neonatal Imaging; Staff Radiologist) Sarah Tracy MD (Surgery Research Fellow)
Approved By	Pediatric Newborn Medicine Clinical Practice Council _pending staff review CWN SPP <u>4/12/17</u> BWH SPP <u>4/19/17</u> BWH NEB <u>05/01/17</u>
Keywords	Necrotizing enterocolitis, abdominal ultrasound, pneumatosis

This is a clinical practice guideline. While the guideline is useful in approaching the diagnosis of newborns with possible necrotizing enterocolitis, clinical judgment and / or new evidence may favor an alternative plan of care, the rationale for which should be documented in the medical record.

I. Purpose

The purpose of this clinical practice guideline is to optimize the diagnostic evaluation of infants with suspected necrotizing enterocolitis (NEC), with goals of earlier confirmation of a NEC diagnosis, avoidance of unnecessary treatment in the absence of NEC, and providing additional information to guide decisions regarding the need for surgical intervention.

II. Scope

Any infant of any gestational age who is undergoing evaluation for NEC.

III. All CPGs will rely on the [NICU Nursing Standards of Care](#). All relevant nursing PPGs *will be listed below*.

--- Relevant nursing PPG links will be forthcoming.

IV. Definitions

The Bell's classification system was developed to stratify patients with NEC per disease severity to aid standardization of management of the patients in each category(1). The original classification was subsequently modified with sub classifications proposed within stages II and III by Walsh and Kleigman in 1986 (2). (Table 1). Most infants initially present with suspected NEC (Bell's stage I) and do not immediately undergo surgical intervention. A prospective cross-sectional survey of 158 level 2 and 3 UK NICUs found that 45% of infants with NEC initially presented as modified Bell's I, 21% modified Bell's II, and 33% modified Bell's III (3).

Table 1 Modified Bell's staging for NEC. (Adapted from Kleigman *et al.*²)

<i>Review of Bell's stages</i>	<i>Clinical findings</i>	<i>Radiographic findings</i>	<i>Gastrointestinal findings</i>
Stage I	Apnea and bradycardia, temperature instability	Normal gas pattern or mild ileus	Gastric residuals, occult blood in stool, mild abdominal distention
Stage II A	Apnea and bradycardia, temperature instability	Ileus gas pattern with one or more dilated loops and focal pneumatosis	Grossly bloody stools, prominent abdominal distention, absent bowel sounds
Stage II B	Thrombocytopenia and mild metabolic acidosis	Widespread pneumatosis, ascites, portal-venous gas	Abdominal wall edema with palpable loops and tenderness
Stage III A	Mixed acidosis, oliguria, hypotension, coagulopathy	Prominent bowel loops, worsening ascites, no free air	Worsening wall edema, erythema and induration
Stage III B	Shock, deterioration in laboratory values and vital signs	Pneumoperitoneum	Perforated bowel

V. Background: abdominal ultrasound for NEC diagnosis

For further background and an excellent review of the literature on abdominal ultrasound for NEC screening and diagnosis, please see appendix B

Abdominal radiographs are the gold standard for diagnostic imaging in the evaluation and follow-up of infants suspected to have NEC. However, there are several known limitations. The character or amount of intraabdominal fluid cannot be assessed with a radiograph. Radiographs may sometimes show a gasless pattern, making it very challenging to interpret what is happening with the bowel. In some cases, bowel perforation can occur without pneumoperitoneum. Up to 37% of neonates with NEC and demonstrated bowel perforation may have a non-diagnostic abdominal radiograph (5).

Point of care ultrasound is already utilized in many NICUs for assistance with invasive procedures including abdominal drain placement, central line placement, and chest tube placement. Because findings may be operator dependent, there can be variability in how such studies are performed and interpreted. Abdominal ultrasound for NEC imaging studies have been utilized in infants to look for adequate motility, signs of bowel necrosis and/or perforation when NEC is suspected (6). The additional use of color Doppler ultrasound to evaluate bowel perfusion is reported to be a helpful adjunct to abdominal

radiography, and absence of flow in the bowel wall is a very sensitive indicator of bowel necrosis (7). There is little standardization of abdominal ultrasound protocols for NEC evaluation. The aim of this clinical practice guideline is to provide guidance regarding a standardized approach to use of abdominal ultrasound to aid in the diagnosis of NEC.

VI. Clinical Practice Guideline:

Appropriate for infants of any gestational age with clinical concern for NEC. Please note that the earliest clinical signs and symptoms of NEC often non-specific to GI pathology.

- Concerning clinical findings may include: apnea, bradycardia, temperature instability, hypotension, oliguria, abdominal distension, bloody stools, feeding intolerance, bilious emesis, abdominal wall edema, abdominal wall erythema/skin discoloration, abdominal tenderness, and palpable loops of bowel.
- Concerning lab findings may include: hyponatremia, hyperkalemia, thrombocytopenia, acidosis, coagulopathy, elevated CRP (13), and neutropenia and/or left shift.

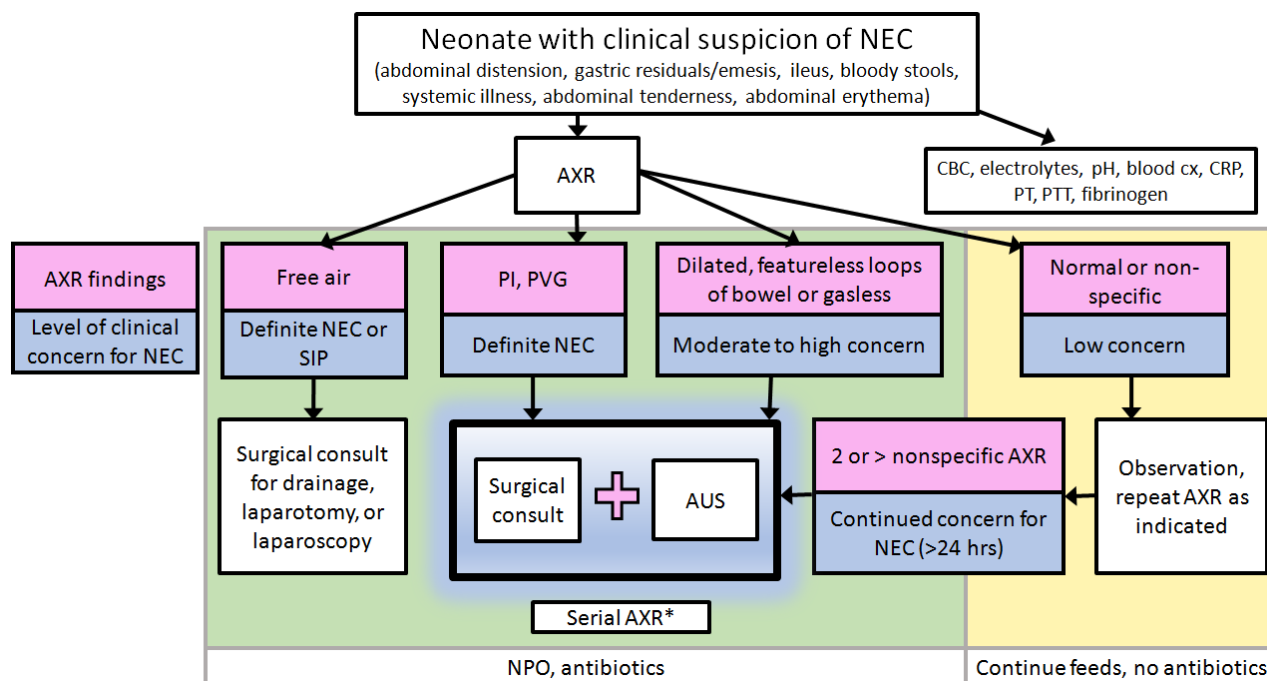
Three proposed uses of the abdominal ultrasound for NEC imaging exam:

1. To evaluate a neonate for suspected necrotizing enterocolitis, as an adjunct to abdominal radiography, physical exam and lab assessment when there is low clinical suspicion but equivocal abdominal radiography.
Goal: to avoid unnecessary medical treatment for necrotizing enterocolitis.
2. To evaluate a neonate with necrotizing enterocolitis for bowel perforation, necrotic bowel, and/or misdiagnosis when an infant is not improving with medical therapy for necrotizing enterocolitis.
Goal: to improve early identification of surgical candidates (patients with non-viable bowel and/or signs of perforation) prior to development of pneumoperitoneum.
3. To evaluate a neonate with necrotizing enterocolitis for perforation, necrotic bowel, and/or misdiagnosis when there is high clinical suspicion but an inconclusive or gasless abdominal radiograph .
Goal: to guide medical management and improve early identification of surgical candidates prior to development of pneumoperitoneum.

The intention is to generate additional information from the interpretation of the **abdominal ultrasound for NEC** exam that will be reported out as either:

- a. No sonographic evidence of necrotizing enterocolitis
- b. Indeterminate findings for necrotizing enterocolitis
- c. Findings concerning for necrotizing enterocolitis

Figure 1: Flow chart of Clinical Practice Guideline for the use of abdominal ultrasound for NEC in the diagnostic evaluation of necrotizing enterocolitis



*NICU team may elect to repeat **abdominal ultrasound for NEC** based on clinical concern.

The decision to pursue **abdominal ultrasound for NEC** is based on initial abdominal radiograph or serial abdominal radiograph findings, in concert with the patient’s overall clinical picture and the clinician’s level of concern. Abdominal radiograph findings may be categorized as normal or non-specific changes (e.g. relative to mild bowel dilatation), or concerning for NEC (dilated, featureless or fixed loops of bowel or gasless abdomen). An abdominal radiographic conclusive finding for NEC would include: pneumatosis intestinalis, portal venous gas or free air. With a finding of free air, an abdominal ultrasound is not indicated. In the setting of pneumatosis intestinalis or portal venous gas, it is proposed that **abdominal ultrasound for NEC** may add additional information that may be useful in guiding surgical decisions.

When a clinical suspicion for NEC is present, a surgical consult should be obtained immediately while ongoing diagnostic evaluation proceeds. A review and examination by surgery, followed by a discussion between neonatology and surgery, should not await the performance of an **abdominal ultrasound for NEC**. The ordering of an **abdominal ultrasound for NEC** should be done in parallel with the initiation of a surgical evaluation.



Abdominal radiography (AXR) is the gold standard imaging study for the evaluation of a neonate with possible necrotizing enterocolitis. All neonates under evaluation will have already had at least one abdominal radiograph and a surgical consult will have been initiated. Repeat AXR should be monitored at a frequency of q4, 6, 8 or 12h hours (or as acutely clinically warranted) depending on the level of clinical concern for severity or evolving abdominal pathology or need for temporal data for diagnosis. If a definitive diagnosis of NEC can be established, the frequency of AXR monitoring can be tapered off once stability has been obtained and clinical improvement is evident on clinical therapy. Abdominal ultrasound for NEC will be ordered if there is greater than a low level of concern, as would be indicated by the infant being made NPO and started on antibiotics. An abdominal ultrasound for NEC with Doppler will be performed at the bedside by a trained BWH sonographer, supervised by a BWH staff radiologist, using a specific protocol/checklist (see appendix A) under the indications provided in Figure 1.

Abdominal ultrasound for NEC INDICATIONS BASED ON AXR FINDINGS:

FREE AIR ON AXR

Any patient who presents with free air on AXR does NOT require **abdominal ultrasound for NEC**. These patients need emergency surgical consult and intervention as the highest priority.

PNEUMATOSIS INTESTINALIS (PI), PORTAL VENOUS GAS (PVG) AND/OR UNCHANGING BOWEL LOOPS ON AXR

- Any patient with symptoms concerning for necrotizing enterocolitis and abnormal AXR findings of pneumatosis intestinalis, portal venous gas, and/or unchanging bowel loops should undergo **abdominal ultrasound for NEC** to confirm findings and rule out evidence of necrotic or perforated bowel.
- A surgical consult should be obtained.
 - If findings are confirmed, and there is no evidence of necrotic or perforated bowel, serial AXR imaging, serial exams, and repeat labs should continue as indicated.
 - If **abdominal ultrasound for NEC** reveals signs of perforation or necrosis, notify surgery immediately and correlate with examination and laboratory findings.

GASLESS OR EQUIVOCAL AXR

- Any patient with symptoms concerning for necrotizing enterocolitis and a gasless or equivocal AXR should undergo **abdominal ultrasound for NEC** to further evaluate.
 - If **abdominal ultrasound for NEC** reveals signs of bowel ischemia, but no evidence of perforation or necrosis, continue to monitor closely with serial AXR, consult surgery.
 - If **abdominal ultrasound for NEC** reveals signs of perforation or necrosis, correlate with examination and laboratory findings, notify surgery ASAP.



NORMAL OR EQUIVOCAL AXR, LOW SUSPICION FOR necrotizing enterocolitis

- Any patient with modified Bell's stage I necrotizing enterocolitis with a normal or equivocal AXR and low clinical suspicion for necrotizing enterocolitis should undergo observation.
- Repeat AXR as indicated.
 - If there is continued or increased concern for necrotizing enterocolitis based on examination or laboratory findings and AXR remains non-diagnostic, consider **abdominal ultrasound for NEC**.

REPORTING OF **abdominal ultrasound for NEC FINDINGS**

Radiology will provide standardized reporting of **abdominal ultrasound for NEC** findings. Radiologists will comment on a low, moderate, or high suspicion for necrotizing enterocolitis based on **abdominal ultrasound for NEC** findings.

VII. Ordering the Abdominal Ultrasound in EPIC

The ultrasound study should be ordered in EPIC as:

Exam: **"US abdomen with vasculature"**

Reason for exam: **"Abnormal prior imaging – radiograph (ID 10512497)"**

Please provide additional clinical context for this exam: **"Concern for necrotizing enterocolitis" [a request has been placed with the EPIC team to add this]**

Comment: **"Please evaluate for ascites and assess bowel as per abdominal US for NEC protocol"**

This exam may be ordered 24/7. As with any ultrasound exam ordered after 12 noon on weekdays, or on weekend days, an order must be placed through eCare and the ultrasound coordinator (beeper 14462) must be paged to arrange for the study. The exam should be initiated by 1 -2 hours after the request. The exam time is approximately 25 minutes. The study will be performed using a L 6-15 ultrasound transducer following the attached 4 quadrant protocol. The attending radiologist can be contacted 24/7 to review the images if done outside of weekday hours. A verbal report can be given, but a final report cannot be signed unless the radiologist is in-house, and therefore may not be available as a final report until the next day. Images will be pushed immediately to Centricity for access through eCare or Centricity.



VIII. Abdominal ultrasound for NEC imaging protocol

The abdominal ultrasound for NEC study will take approximately 25 minutes, and will be done by a trained sonographer (ultrasound technologist) following the described pre-determined protocol. The abdominal ultrasound will be performed with a L 6-15 transducer to assess the 4 quadrants for intraabdominal fluid and its character and free air. An assessment will be made for portal venous gas. Bowel loops will be evaluated in each of the four quadrants. All quadrants will be interrogated with gray-scale and color Doppler US in real time, and sample static images and cine loops will be obtained in each quadrant where the most loops are concentrated.

A radiologist will then report the results of the examination by standard abnormal ultrasound result reporting protocol. Image files will be immediately downloaded from the portable unit to the picture archiving and communication system so that images will be accessible to the clinicians.

Gray-scale US evaluation included assessment of bowel wall echotexture for normal stratified bowel appearance or loss of "gut signature," measurement of wall thickness with calipers, and determination of the presence of intramural air and peristalsis. Peristalsis will be assessed according to the presence or absence of bowel contractions during 1 minute. Normal bowel wall thickness will be considered between 1.1 and 2.6 mm.

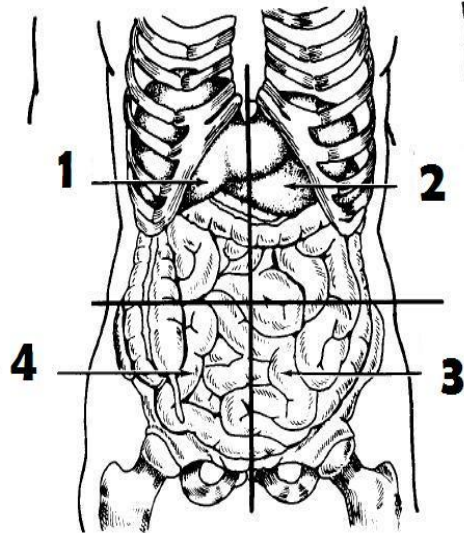
Color Doppler US will be used to evaluate intestinal mural blood flow with a standard protocol and parameters including the lowest possible pulse repetition frequency without aliasing, a low wall filter, and the highest Doppler gain settings without flash artifacts. Velocity will be set at 0.029 – 0.11 m/sec. Color Doppler flow will be determined to be present when color Doppler signals are reproducible or confirmed with pulsed Doppler waveforms. Bowel loops will be compared with adjacent loops. When bowel loops without mural blood flow are identified, the settings will be changed to more sensitive settings in an attempt to detect the slowest possible velocities down to 0.029 m/sec, below which only flash artifacts are obtained.



APPENDIX A: Abdominal ultrasound for NEC checklist

CHECK LIST: ABDOMINAL ULTRASOUND FOR NEC

	QUAD 1		QUAD 2		QUAD 3		QUAD 4	
Free air	Y	N	Y	N	Y	N	Y	N
Portal venous gas	Y	N						
Simple free fluid	Y	N	Y	N	Y	N	Y	N
Complex/echogenic free fluid	Y	N	Y	N	Y	N	Y	N
Focal fluid collection	Y	N	Y	N	Y	N	Y	N
Peristalsis (normal >10 in 1 min)	Y	N	Y	N	Y	N	Y	N
Wall thickness (normal = 1.1mm-2.6mm)								
Echogenic bowel wall	Y	N	Y	N	Y	N	Y	N
Intramural gas	Y	N	Y	N	Y	N	Y	N
Dilatation	Y	N	Y	N	Y	N	Y	N
Mural flow (V= 0.086 m/s)								
Comments								



CHECKLIST DETAILS

- Presence of free air (echogenicities lines or foci with posterior ring-down or comet tail artifacts)
- Portal venous gas (punctuate or linear echogenicities noted within the main portal vein or its intrahepatic branches)
- Presence of free intraperitoneal fluid and focal fluid collections
- Peristalsis (presence/absence and efficacy of bowel contractions > 10 in 1 min)
- Bowel wall structure (measure wall thickness with callipers, normal range 1.1-2.6 mm)
- Echogenic bowel wall
- Presence of Intramural gas (punctuate or granular echogenicities within the bowel wall)
- Bowel dilatation
- Mural flow in each of the 4 quadrants ($V = 0.086$ m/s)
 - Hyperaemia= markedly increased colour Doppler signal
 - Normal
 - Low Mural Flow= markedly decreased
 - Absence

Based on Faingold et al 2005 and Karolinska checklist (unpublished) 2012



APPENDIX B: Further background and review of the literature

Point of care ultrasound is already utilized in many neonatal intensive care units for assistance with invasive procedures including abdominal drain placement, central line placement, and chest tube placement. Because findings may be operator dependent, there can be variability in how such studies are performed and interpreted. Abdominal ultrasound for NEC imaging studies have been utilized in infants to look for adequate motility, signs of bowel necrosis and/or perforation when necrotizing enterocolitis is suspected (6). The additional use of color Doppler ultrasound to evaluate bowel perfusion is reported to be a helpful adjunct to abdominal radiography. The absence of flow in the bowel wall is a very sensitive indicator of bowel necrosis (7). However, there is little standardization of abdominal ultrasound protocols for NEC evaluation. Some centers have used abdominal ultrasound to identify early signs of bowel change in patients with possible NEC (Bell's I). This information can guide a clinician who is unsure about whether to initiate medical therapy for NEC. Other centers use abdominal ultrasound to identify early signs of perforation in patients with moderate or severe NEC, (Bell's II-III) which may influence decisions regarding surgical intervention.

Presentation with lower stages of the Bell's classification system has not been proven to be predictive of mortality, as patients who present as Bell's stage I or II may progress to Bell's stage III, developing shock and perforation. It is challenging to predict which neonates will progress to require surgery and which will improve with medical therapy. Many factors play a role in the decision to operate on a neonate with necrotizing enterocolitis. Imaging reports are important for surgical decision-making, and a critical imaging report or acute clinical deterioration often convinces a surgeon that a neonate requires an intervention (4).

In a cohort of 67 patients with either suspected necrotizing enterocolitis (Bell's I), or age-matched non-necrotizing enterocolitis controls, abdominal ultrasound did not reveal significant differences in bowel wall thickness, bowel wall echogenicity or color Doppler perfusion (8). A retrospective review of 40 neonates with Bell's I necrotizing enterocolitis who underwent serial abdominal ultrasound revealed that 80% of the abnormal findings on the first exam were not seen on follow-up exams after the initiation of medical treatment with antibiotics and bowel rest (9). Findings from both studies suggest that bowel sonography may be helpful for the early diagnosis and monitoring of patients with necrotizing enterocolitis, and serial abdominal ultrasound may be helpful for determining when it may be safe to begin re-feeding (not addressed in this CPG).



color Doppler ultrasound may provide additional information to that of gray scale sonography in the evaluation of necrotizing enterocolitis and may help identify patients before medical management fails, perforation occurs and bowel resection if required (7). In a prospective single institution study of 60 neonates, absence of flow on color Doppler was 100% sensitive and 90% specific for bowel necrosis, with a positive predictive value of 83% (CI 55-95%) and a negative predictive value of 100%. In neonates with severe (modified Bell's stage III) necrotizing enterocolitis, absence of flow on color Doppler was more sensitive (100%) than free air on abdominal radiography (40%) for identifying bowel necrosis.

A prospective study in a population of Bell's II-III patients underwent standard radiography and **abdominal ultrasound for NEC** with color Doppler. Five of 26 patients had signs of intestinal necrosis on **abdominal ultrasound for NEC** and underwent laparotomy prior to perforation or clinical deterioration. Four of the 5 patients that underwent laparotomy had intestinal necrosis requiring resection (10). The use of **abdominal ultrasound for NEC** with color Doppler in patients with definite necrotizing enterocolitis who have the highest mortality risk may lead to improvement in outcomes with with early laparotomy.

Another prospective study of **abdominal ultrasound for NEC** in 93 neonates with necrotizing enterocolitis at all Bell's stages (I-III) used an ultrasound protocol without color Doppler. They hypothesized that **abdominal ultrasound for NEC** was superior to abdominal radiography for identifying necrotic bowel or perforation. Three of the patients with necrotizing enterocolitis who underwent abdominal drain placement for clinical deterioration had echogenic free fluid on **abdominal ultrasound for NEC**, but no free air on abdominal radiograph(11), suggesting that **abdominal ultrasound for NEC** may be superior to radiographs for early detection of intestinal perforation. Abdominal free fluid characteristics can be helpful for diagnosis. In a retrospective review of 238 necrotizing enterocolitis patients who underwent **abdominal ultrasound for NEC** and abdominal radiography, echogenic free fluid was the most specific (88.6%) predictor of necrotizing enterocolitis in patients without free air who required surgery (12).

References

1. Bell MJ, Ternberg JL, Feigin RD, Keating JP, Marshall R, Barton L, Brotherton T. Neonatal necrotizing enterocolitis. Therapeutic decisions based upon clinical staging. *Ann Surg.* 1978 Jan;187(1):1-7. PubMed PMID: 413500; PubMed Central PMCID: PMC1396409.
2. Walsh MC, Kliegman RM. Necrotizing enterocolitis: treatment based on staging criteria. *Pediatr Clin North Am.* 1986 Feb;33(1):179-201. Review. PubMed PMID: 3081865.
3. Rees CM, Eaton S, Pierro A. National prospective surveillance study of necrotizing enterocolitis in neonatal intensive care units. *J Pediatr Surg.* 2010 Jul;45(7):1391-7. doi: 10.1016/j.jpedsurg.2009.12.002. PMID: 20638514
4. He Y, Zhong Y, Yu J, Cheng C, Wang Z, Li L. Ultrasonography and radiography findings predicted the need for surgery in patients with necrotising enterocolitis without pneumoperitoneum. *Acta Paediatr.* 2016 Apr;105(4):e151-5. doi: 10.1111/apa.13315. Epub 2016 Jan 20. PubMed PMID: 26676409.
5. Miller SF, Seibert JJ, Kinder DL, Wilson AR. Use of ultrasound in the detection of occult bowel perforation in neonates. *J Ultrasound Med.* 1993 Sept 12(9): 531-5. PubMed PMID: 8107185.
6. Epelman M, Daneman A, Navarro OM, Morag I, Moore AM, Kim JH, Faingold R, Taylor G, Gerstle JT. Necrotizing enterocolitis: review of state-of-the-art imaging findings with pathologic correlation. *Radiographics* 2007 Mar-Apr;27(2):285-305. Doi: 10.1148/rg.272055098. PubMed PMID: 17374854.
7. Faingold R, Daneman A, Tomlinson G, Babyn PS, Manson DE, Mohanta A, Moore AM, Hellmann J, Smith C, Gerstle T, Kim JH. Necrotizing enterocolitis: assessment of bowel viability with color Doppler US. *Radiology.* 2005 May;235(2):587-94. PubMed PMID: 15858098.
8. Kamali K, Hosseini SR, Ardakani SM, Farnoodi MR. Complementary value of sonography in early evaluation of necrotizing enterocolitis. *Pol J Radiol.* 2015 Jun 19;80:317-23. PubMed PMID 26150903.
9. Kim WY, Kim WS, Kim IO, Kwon TH, Chang W, Lee EK. Sonographic evaluation of neonates with early-stage necrotizing enterocolitis. *Pediatr Radiol.* 2005 Nov; 35(11): 1056-61. Epub 2003 Aug 3. PubMed PMID 16078076.
10. Yikilmaz A, Hall NJ, Daneman A, Gerstle JT, Navarro OM, Moineddin R, Pleasants H, Pierro A. Prospective evaluation of the impact of sonography on the management of neonates with necrotizing enterocolitis. *Pediatr Surg Int.* 2014 Dec;30(12):1231-40. PubMed PMID 25327619.
11. Dilli D, Suna Oğuz S, Erol R, Ozkan-Ulu H, Dumanlı H, Dilmen U. Does abdominal sonography provide additional information over abdominal plain radiography for diagnosis of necrotizing enterocolitis in neonates? *Pediatr Surg Int.* 2011 Mar;27(3):321-7. PubMed PMID: 20938666.
12. He Y, Zhong Y, Yu J, Cheng C, Wang Z, Li L. Ultrasonography and radiography findings predicted the need for surgery in patients with necrotising enterocolitis without pneumoperitoneum. *Acta Paediatr.* 2016 Apr;105(4):e151-5. doi: 10.1111/apa.13315. Epub 2016 Jan 20. PubMed PMID: 26676409.
13. Pourcyrus M, Korones, SB, Yang W, Boulden TF, Bada HS. C-Reactive Protein in the Diagnosis, Management, and Prognosis of Neonatal Necrotizing Enterocolitis. *Pediatrics* 2005 116 (5):1064 – 1069.